

Evaluation of Complications Following a Trans-masseteric Antero-parotid Approach for Patients with Sub-condylar Fractures of Their Temporomandibular Joint. A Retrospective Study

Vladimír Machoň, Avni Desai, Jitka Levorová, Dušan Hirjak, Eitan Brizman, René Foltán

Department of Dental Medicine, First Faculty of Medicine, Charles University and General University Hospital in Prague, Prague, Czech Republic

Received February 17, 2019; Accepted September 4, 2019.

Key words: Sub-condylar fractures – Mandible – Trans-masseteric antero-parotid approach

Abstract: Sub-condylar fractures of the temporomandibular joint can be treated by an extraoral or intraoral approach. Trans-masseteric antero-parotid approach (TMAP) is an extraoral approach utilising a retromandibular incision. The authors evaluated patients' status and any complications of using TMAP from the years 2013–2017. There were 39 patients (44 fractures). When using TMAP, in 43 fractures the fragments were favourably positioned, in one case the position was compromised. Of the complications, postoperative palsy of the facial nerve was reported 6.8% – in all cases this was only temporary. Late occlusion had an equal number of complications (in 2 cases this was as a result of an infectious complication of the wound, and in 2 cases due to resorption of the proximal fragment). Muscular pain and dysfunction of the temporomandibular joint following trauma were observed consistently in 6.8% of patients. Sialocele, a non-conforming scar, and infectious complications were observed in 4.5% of patients. TMAP allows rapid surgical performance, with a good view for perfect repositioning and fixation of fragments of sub-condylar fractures of the temporomandibular joint. The complications associated with this approach are, for the most part, temporary, the aesthetic handicap of a scar is considered by patients to be acceptable. Overall, it is possible to evaluate retromandibular TMAP as safe, and the authors recommended it for treatment of sub-condylar fractures of the mandible.

Mailing Address: Vladimír Machoň, MD., Department of Dental Medicine, First Faculty of Medicine, Charles University and General University Hospital in Prague, U Nemocnice 2, 120 00 Prague 2, Czech Republic; e-mail: machonv@seznam.cz

Introduction

Temporomandibular joint fractures belong to the most common fractures of the facial skeleton, forming 25 to 35% of all fractures of the lower jaw. They can be classified as fractures of the articular head (intra-articular), the articular neck, and sub-condylar fractures. Treatment of joint fractures can be conservative (non-surgical) or surgical. Conservative treatment comprises of a soft diet, temporary intermaxillary fixation and rehabilitation of mouth opening. The principle of surgical treatment consists of open reduction of the fragments into their anatomical position and then stable fixation by osteosynthesis (ORIF). Access for open reduction and internal fixation may include, pre-auricular, end-aural, posterior-auricular, retromandibular, subangular, submandibular and intraoral approaches (Eckelt and Loukota, 2010; Leiser et al., 2013; Spinzia et al., 2014).

The authors have evaluated the use of a retromandibular trans-masseteric antero-parotid approach in the surgical treatment of sub-condylar fractures.

Material and Methods

The group consisted of patients with sub-condylar fractures of their joints, treated by open reduction and internal fixation between January 2013 and May 2017, all by a retromandibular trans-masseteric antero-parotid approach (TMAP).

There was a total of 44 fractures in 39 patients (22 men and 17 women) with an average age of 39.5 years (age 18 to 73 years). Four patients had bilateral sub-condylar fractures together with fractures of their mandible, one case was a bilateral sub-condylar fracture, 9 patients had unilateral sub-condylar fractures together with a fracture of their mandible, 2 patients had sub-condylar fractures along with a mid-face fracture. 23 patients had isolated sub-condylar fractures. In two cases the sub-condylar fracture was comminuted.

In 15 cases, the proximal fragment was displaced medially, in 22 cases the mandible was shortened, with lateral displacement of the proximal fragment, in 4 cases the mandible had medial displacement of the proximal fragment and was truncated, in 2 cases the proximal fragment was dislocated in front of the articular prominence.

Aetiological factors contributing to the development of the sub-condylar fractures included, falling onto their face (21 patients), assault (11 patients), bicycle accident (4 patients), one fracture from a car crash, one head clash whilst playing football, one blow from a dog's head.

All patients were examined and treated by the same surgical team at First Faculty of Medicine, Charles University and General University Hospital in Prague.

The aim of this work was to evaluate the complications related to this relatively rarely used surgical approach.

Operative technique (Figures 1–5)

All operations were performed under general anaesthetic via nasotracheal intubation.

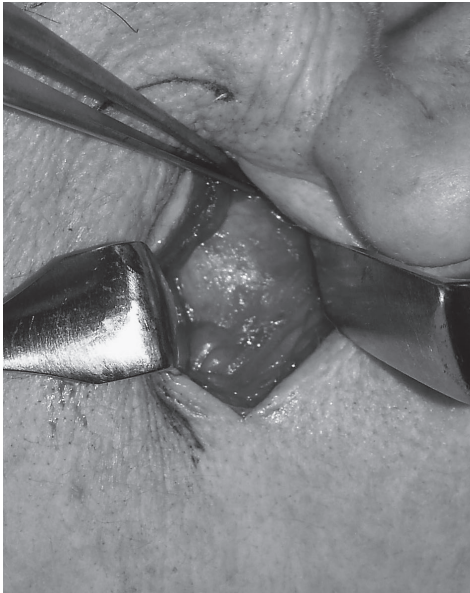


Figure 1 – Retromandibular incision.

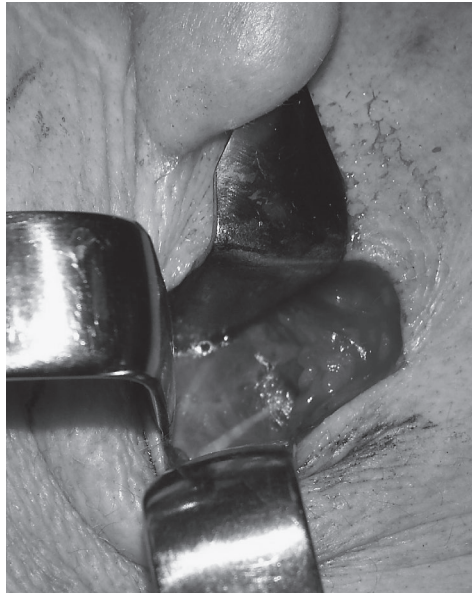

Figure 2 – Masseter muscle and facial nerve branches.

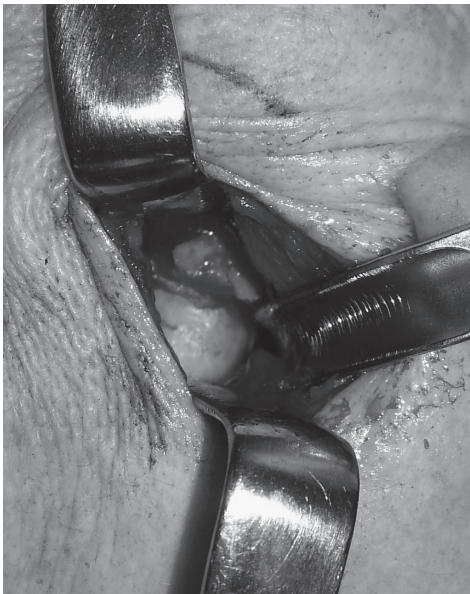

Figure 3 – Reposition of fracture.

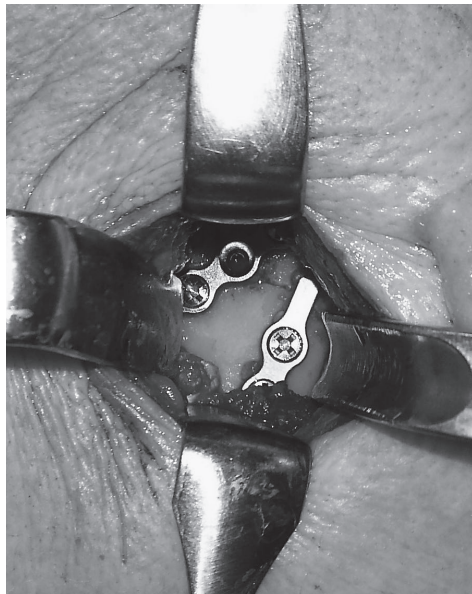
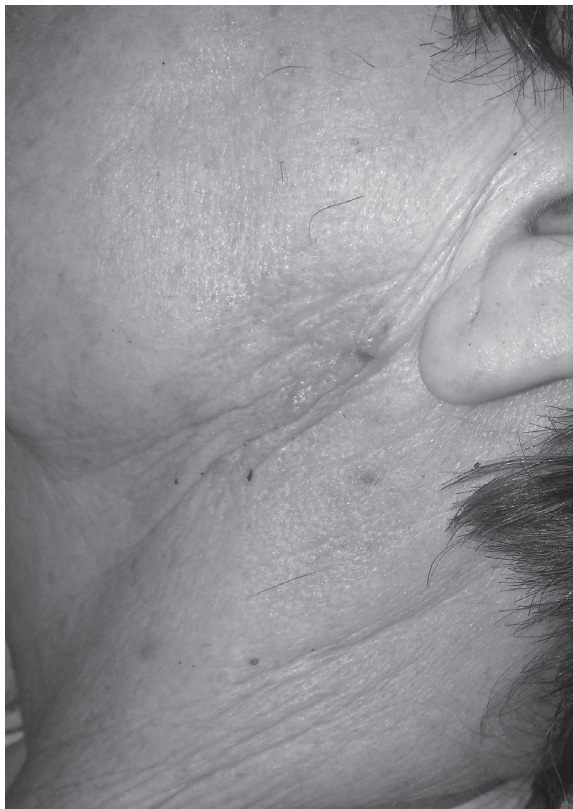

Figure 4 – Osteosynthesis with two miniplates.

The operation began with the placement of IMF (intermaxillary fixation) screws (3 into each jaw) followed by inter-maxillary fixation with elastic bands (between the opposing MMF – mandibulo-maxillary fixation screws and then crossed between

Figure 5 – Retromandibular incision, 2 months after surgery.



the screws). Next a 2-cm vertical retromandibular skin incision was done – behind the edge of the mandible, revealing the capsule of the parotid gland. Blunt dissection superficial to the capsule to expose the anterior edge of the gland, which was then retracted posteriorly. The masseter muscle was then penetrated (between visualized branches of the facial nerve) leading to the external surface of the mandible, which would be chased to the location of the sub-condylar fracture. DePuy Synthes osteosynthesis material (Johnson and Johnson, USA) was used to fix the fragments utilising: 2 straight plates (25 fractures), a trapezoidal plate (TCP – 12 fractures), an L-shaped plate (in 7 fractures).

After fixation of the fracture and irrigation of the surgical wound, a suction drain was sutured in place for all cases, followed by closure of the wound – sutured in layers (Wilson et al., 2005; Biglioli and Colletti, 2008; Eckelt and Loukota, 2010).

Finally, the elastic intermaxillary fixation was removed and the occlusion was confirmed. Simple elastic fixation was left on for patients with complex (multiple) fractures for 10–14 days, as well as for patients with comminuted fractures. In patients with isolated sub-condylar fractures, the intermaxillary fixation was removed at the end of the operation.

Postoperative care

Drains were removed 24 hours after surgery. A mixed diet was recommended for patients for the first 4 weeks, and a soft diet from the 4th to 6th week. Antibiotics were prescribed for the first week after surgery (Co-Amoxiclav, or for patients who were allergic to penicillin – Clindamycin).

For the 1st week after surgery, patients were recommended to open their mouths as little as possible. From the next week they were advised – to gradually and increasingly open, until it starts to become painful. Intense rehabilitation began if limited opening (less than 30 mm) was seen in the 5th postoperative week. In cases of facial nerve weakness, facial functional rehabilitation started from the 1st postoperative day.

Patient check-up

10 to 14 days after surgery (for removal of stitches), then one month, 3 months, 6 months, and 1 year after surgery. At each check-up, an assessment of the patients' mouth-opening, presence of pain, surgical wound condition, facial nerve function, temporomandibular joint (TMJ) function and occlusion status were made. Radiographic examination from 2 different projections was performed on the 2nd postoperative day and then at 3 months and 12 months after surgery. From 2015, cone beam CT (CBCT) was routinely used instead of plain-film (digital) X-rays.

Results

Upon clinical examination, correct occlusion was achieved for all patients immediately following surgery. However, according to the X-ray or CBCT images, on the 2nd postoperative day one case did not appear to have an ideal proximal fragment position (but as their occlusion was functional, there was no indication for further reposition). In all other cases, though, replication of the ideal position for the proximal fragment was achieved.

The average operating time from the start of IMF screw insertion until completion of suturing of the surgical wound was 56.34 minutes.

Pain rating: one month after surgery, pain was present in 3 patients (VAS > 2), pain was not otherwise noted in any other patients.

Assessment of mouth-opening: one month after surgery, 9 patients experienced mouth opening of less than 30 mm, by 6 weeks after surgery the mouth-opening of all patients had improved to more than 35 mm, as was noted in subsequent inspections.

Postoperative complications

- Facial nerve dysfunction was observed after surgery in 3 fractures (6.8%), all of these were resolved 1 week after surgery. Permanent dysfunction did not occur. Resolution always occurred after targeted facial nerve functional rehabilitation.

- Sialocoele was observed in 2 fractures (4.5%). This was resolved by repetitive drainage, leading to gradual resolution within 2 weeks.
- Masseter muscle pain – present in 3 fractures (6.8%), in all cases this was resolved with targeted relaxation massage, thermotherapy (application of dry heat 3× daily for 5 minutes). All patients improved their condition, eliminating muscle pain within 2 months of their surgery.
- Inflammatory complications at the surgical site were observed in 2 fractures – associated with redness, swelling and laboratory-proven inflammatory markers. In both cases, the complications were treated with surgical wound drainage and prolonged use of antibiotics. The patients' intermaxillary fixation were reinstated (for the duration of inflammation).
- “Increased” scarring was present after the treatment of 2 fractures, both were the cases when the patients had been treated for inflammatory complications.
- Malocclusion was observed postoperatively in 4 fractures (9%). In one case, there was non-union of the proximal fragment, in one case progressive resorption of the proximal fragment occurred (the patient began to see a change in their bite 3 months after the trauma). In 2 cases, the osteosynthetic material got loosen due to an inflammatory process. This subsequently led to dislocation of the proximal fragment. In 2 cases the situation was resolved by total joint replacement, in the remaining 2 cases the patients refused further surgery.
- TMJ dysfunction in the sense of pain-free clicking (locked closed), was reported post-operatively after 3 fractures (6.8%). It was addressed by TMJ physiotherapy.

Discussion

Low sub-condylar fractures usually require an external (submandibular, subangular, retromandibular) approach, or an intraoral (endoscopically assisted) approach. The choice of access to the fracture is determined by operative experience, and available equipment – especially the specific instruments required for an intraoral endoscopically assisted approach (Eckelt and Loukota, 2010).

The use of an external approach (versus an intraoral approach) brings with it a large number of possible complications, including dysfunction of the facial nerve, sialocoele, salivary fistula, Frey's syndrome and, last but not least, the presence of a postoperative scar. Risk of haematoma, infectious complications, or fragment malunion are equally common for both approaches (Eckelt and Loukota, 2010; Al-Moraissi et al., 2018; Rozeboom et al., 2018).

The retromandibular approach was first described in 1967 as an external approach to vertical sub-condylar osteotomy (Hinds and Girotti, 1967), and was subsequently used as an approach for the treatment of sub-condylar fractures. The length of cut in the retromandibular approach may vary. The cut is guided by the jaw edge under the earlobe (Eckelt and Loukota, 2010), and the incision can be extended pre-auricularly (Wilson et al., 2005; Salgarelli et al., 2013) or to the posterior auricular region (Choi, 2015). The authors have only utilised the retromandibular access for TMAP

as published by Biglioli and Colletti (2008). This approach enabled the authors to have an adequate operative field for repositioning and fixation of the fragments; in the authors' work, an unsatisfactory anatomical reduction only occurred perioperatively in one case.

Retromandibular access can be gained in three ways – trans-masseteric antero-parotid, trans-masseteric subcutaneous or the most commonly used – trans-parotid approach (Eckelt and Loukota, 2010; Al-Moraissi et al., 2018; Bruneau et al., 2018; Rozeboom et al., 2018). According to a review published by Rozeboom et al. (2018) (70 studies, 2,783 patients), 59.4% used the trans-parotid retromandibular approach and 12.5% a non-trans-parotid approach.

The most frequent risk of external approach to TMJ fractures is injury to the facial nerve – which is located directly within the operative field. Al-Moraissi et al. (2018), in the systemic review, evaluated facial nerve injuries in 96 studies (a total of 3,873 patients with articular fractures); the incidence of temporary hypofunction of the facial nerve was between 0 and 19%, with 0.3–2.2% reporting persistent hypofunction of the facial nerve. In the review of Al-Moraissi et al. (2018), the risk of temporary facial nerve injury in sub-condylar fractures accessed from a retromandibular incision using a trans-parotid approach with facial nerve preparation was 11.8%, using a trans-parotid approach without nerve preparation 10.5%, trans-masseteric antero-parotid approach 3.3%, and in a trans-masseteric antero-parotid approach extending pre-auricularly 2.3%. As the branches of the facial nerve are well visualized within the operative field, transient paresis is most often caused by postoperative swelling or retraction of the nerve perioperatively (Wilson et al., 2005; Eckelt and Loukota, 2010). Kanno et al. (2016) showed a significantly higher risk of transient paralysis of the facial nerve in dislocated fractures. Only TMAP was used in the authors' work, and facial nerve hypofunction was recorded in 3 cases (6.8%), with hypofunction in all cases temporary, and complete function restored within 1 week. The higher percentage of temporary facial nerve palsy may be related to the fact that a mini-retromandibular approach was used in all cases, necessitating a greater pressure by retractors on the surrounding tissues (including the branches of the facial nerve).

Other postoperative complications are related to the parotid gland. Rozeboom et al. (2018) presented a review of the risk of sialocoele as 2.33% and salivary fistula as 4.3% when using external access, these risks being mainly associated with the trans-parotid approach. For the antero-parotid trans-masseteric approach, this complication is referred to as zero by a series of authors (Wilson et al., 2005; Trost et al., 2009; Narayanan et al., 2012; Leiser et al., 2013; Salgarelli et al., 2013), as access by careful preparation occurs superficially to the glandular capsule. However, even during this preparation, the integrity of the capsule may be compromised. In the authors' work, sialocoele was a postoperative complication in 2 patients (4.5%).

28.6% of patients in the review by Rozeboom et al. (2018) suffer from the postoperative complication of an (aesthetically) unsatisfactory scar. In the authors'

work, an unsatisfactory scar was reported in 2 patients (4.5%), but in both cases, the surgical wounds had been complicated by infection. In all other cases (where there was physiological healing), the scar was assessed by the patients to be satisfactory. Similar results are reported by Bruneau et al. (2018) (wound dehiscence occurred in 1 patient out of 43 operated – 2.3%).

Infectious complications were noted in the authors' work in 2 patients (4.5%), in both cases comminuted fractures. Similar results were reported by Trost et al. (2009). Rozeboom et al. (2018) then gave an overall incidence of inflammatory complications as 2.7%, with the retromandibular approach being most at risk of this. The onset of infection may be related to haematoma retention at the surgical wound site, prolonged operating time, and infection of the surgical wound by the perioperative introduction of intermaxillary fixation (Eckelt and Loukota, 2010).

Similar to other authors presenting TMAP (Wilson et al., 2005; Trost et al., 2009; Narayanan et al., 2012; Leiser et al., 2013), Frey's syndrome was not reported in the authors' work. However, Rozeboom et al. (2018) indicated a total incidence of 0.74% for external approaches (most often in approaches using a retromandibular incision).

Another complication related to TMAP is muscle pain – resulting from postoperative muscle contraction or muscle scarring (Eckelt and Loukota, 2010). In the authors' work, muscle pain was observed in 3 patients (6.8%), eliminated by targeted postoperative muscular rehabilitation. Postoperative muscle contraction was related to a limitation of jaw movement. In the authors' work, an abduction limitation (MIO below 30 mm) was seen in 9 patients (23%) 6 weeks after surgery. In later check-ups, opening had been improved by physiotherapy and rehabilitation. These results are in agreement with other authors (Trost et al., 2009; Leiser et al., 2013).

The other complications reported in the results were not directly related to the operational approach used. These included a postoperative occlusion disorder, infection, and a functional TMJ disorder.

The most common cause of an unsatisfactory postoperative occlusion was the insufficient use of perioperative intermaxillary fixation or insufficient reduction of the proximal fragment. These occlusion disorders were noticed by the patient immediately after surgery (Eckelt and Loukota, 2010). Disorders of occlusion occurred in 2 cases, 3 weeks after surgery; in both cases, the patients had suffered postoperative wound infection, followed by loosening of the osteosynthesis and dislocation of the proximal fragment. In one case, resorption occurred after fragment union, and the patient experienced a change in their occlusion 3 months after surgery. In one case, there was non-union between the proximal fragment and the mandible, and its subsequent resorption. Avascular necrosis of the joint head, leading to its' resorption, often presents after extensive stripping of tissues from the proximal fragment, or even by its removal from the surgical wound and subsequent re-insertion. However, damage to the bony structure initially occurs due

to the force of impact from their original trauma (Eckelt and Loukota, 2010). The cause of necrosis was not demonstrated by the authors of this study – the proximal fragment was never removed from the wound and the authors were not aware of any extensive stripping of the muscles.

TMJ dysfunction detected by audible TMJ phenomena was due to dislocation and reposition of the disc. One of the aetiological factors behind disc dislocation is trauma (Laskin et al., 2006), however, disc dislocation with a fracture of the articular joint cannot be objectively assessed because it relies purely on patients informing us that they did not suffer from this prior to their trauma. Overall, TMJ pathological conditions are reported as uncommon complications (Eckelt and Loukota, 2010).

Conclusion

A trans-masseteric antero-parotid approach facilitates rapid surgical performance with a good visual field, enabling an accurate reduction and fixation of sub-condylar fractures of the TMJ. The complications associated with this approach are, for the most part, temporary, and the relatively poor aesthetics of a scar is considered acceptable by patients. Overall, it is possible to evaluate the TMAP approach as safe, and the authors recommended it for the treatment of sub-condylar fractures of the mandible.

References

- Al-Moraissi, E. A., Louvrier, A., Colletti, G., Wolford, L. M., Biglioli, F., Ragaey, M., Meyer, C., Ellis, E. 3rd (2018) Does the surgical approach for treating mandibular condylar fractures affect the rate of seventh cranial nerve injuries? A systematic review and meta-analysis based on a new classification for surgical approaches. *J. Craniomaxillofac. Surg.* **46(3)**, 398–412.
- Biglioli, F., Colletti, G. (2008) Mini-retromandibular approach to condylar fractures. *J. Craniomaxillofac. Surg.* **36(7)**, 378–383.
- Bruneau, S., Courvoisier, D. S., Scolozzi, P. (2018) Facial nerve injury and other complications following retromandibular subparotid approach for the management of condylar fractures. *J. Oral Maxillofac. Surg.* **76(4)**, 812–818.
- Choi, M. G. (2015) Transmasseteric antero-parotid facelift approach for open reduction and internal fixation of condylar fractures. *J. Korean Assoc. Oral Maxillofac. Surg.* **41(3)**, 149–155.
- Eckelt, U., Loukota, R. (2010) *Fractures of the Mandibular Condyle: Approaches and Osteosynthesis*. Eberl Medien GmbH, Immenstadt im Allgäu.
- Hinds, E. C., Girotti, W. J. (1967) Vertical subcondylar osteotomy: a reappraisal. *Oral Surg. Oral Med. Oral Pathol.* **24(2)**, 164–170.
- Kanno, T., Sukegawa, S., Tatsumi, H., Karino, M., Nariai, Y., Nakatani, E., Furuki, Y., Sekine, J. (2016) Does a retromandibular transparotid approach for the open treatment of condylar fractures result in facial nerve injury? *J. Oral Maxillofac. Surg.* **74(10)**, 2019–2032.
- Laskin, D. M., Greene, C. S., Hylander, W. L. (2006) *Temporomandibular Disorders: An Evidenced-based Approach to Diagnosis and Treatment*, 1st Edition. Quintessence Pub. Co., Batavia.
- Leiser, Y., Peled, M., Braun, R., Abu-El Naaj, I. (2013) Treatment of low subcondylar fractures – a 5-year retrospective study. *Int. J. Oral Maxillofac. Surg.* **42(6)**, 716–720.

- Narayanan, V., Ramadorai, A., Ravi, P., Nirvikalpa, N. (2012) Transmasseteric anterior parotid approach for condylar fractures: experience of 129 cases. *Br. J. Oral Maxillofac. Surg.* **50(5)**, 420–424.
- Rozeboom, A. V. J., Dubois, L., Bos, R. R. M., Spijker, R., de Lange, J. (2018) Open treatment of condylar fractures via extraoral approaches: A review of complications. *J. Craniomaxillofac. Surg.* **46(8)**, 1232–1240.
- Salgarelli, A. C., Anesi, A., Bellini, P., Pollastri, G., Tanza, D., Barberini, S., Chiarini, L. (2013) How to improve retromandibular transmasseteric anteroparotid approach for mandibular condylar fractures: our clinical experience. *Int. J. Oral Maxillofac. Surg.* **42(4)**, 464–469.
- Spinzia, A., Patrone, R., Belli, E., Dell'Aversana Orabona, G., Ungari, C., Filiaci, F., Agrillo, A., De Riu, G., Meloni, S. M., Liberatore, G., Piombino, P. (2014) Open reduction and internal fixation of extracapsular mandibular condyle fractures: a long-term clinical and radiological follow-up of 25 patients. *BMC Surg.* **14**, 68.
- Trost, O., Trouilloud, P., Malka, G. (2009) Open reduction and internal fixation of low subcondylar fractures of mandible through high cervical transmasseteric anteroparotid approach. *J. Oral Maxillofac. Surg.* **67(11)**, 2446–2451.
- Wilson, A. W., Ethunandan, M., Brennan, P. A. (2005) Transmasseteric antero-parotid approach for open reduction and internal fixation of condylar fractures. *Br. J. Oral Maxillofac. Surg.* **43(1)**, 57–60.