

Amyand's Hernia: an Up-to-Date Review of the Literature

Dimitrios Patoulias^{1,*}, Maria Kalogirou², Ioannis Patoulias²

ABSTRACT

Amyand's hernia is defined as an inguinal hernia, containing the appendix within the hernia sac. Incidence of this rare condition rises up to 1% (0.19–1.7%) of all inguinal hernia cases. Inflammation of the appendix within the inguinal sac is even rarer, as it corresponds to 0.1% (0.07–0.13%) of all Amyand's hernia cases. After a comprehensive review of the limited relevant literature, we aim through this review study to describe the pathophysiology of inflammation of the appendix – contained in the hernia sac – and present the latest data about the diagnostic approach and surgical treatment of Amyand's hernia.

KEYWORDS

inguinal hernia; appendix; acute appendicitis; appendectomy; child

AUTHOR AFFILIATIONS

¹ Department of Internal Medicine, General Hospital of Veria, Veria, Greece

² 1st Department of Pediatric Surgery, Aristotle University of Thessaloniki, General Hospital "G. Gennimatas", Thessaloniki, Greece

* Corresponding author: M. Alexandrou 3B, Peuka, Thessaloniki, Postal code 57010, Greece; e-mail: dipatoulias@gmail.com

Received: 14 March 2017

Accepted: 11 August 2017

Published online: 5 February 2018

Acta Medica (Hradec Králové) 2017; 60(3): 131–134

<https://doi.org/10.14712/18059694.2018.7>

© 2017 The Authors. This is an open-access article distributed under the terms of the Creative Commons Attribution License (<http://creativecommons.org/licenses/by/4.0>), which permits unrestricted use, distribution, and reproduction in any medium, provided the original author and source are credited.

DEFINITION AND HISTORY

Amyand's hernia is defined as an inguinal hernia, containing the appendix within the hernia sac. In 1735 C. Amyand described the first case of incarcerated inguinal hernia, containing a perforated appendix, in an 11-year-old boy (1). The patient underwent simultaneous ligation of the hernia sac and appendectomy. Historically, it was the first conducted appendectomy (2). It should not be confused with femoral hernia containing the appendix. The latter was named De Garengeot hernia after Rene Jacques Croissant De Garengeot, who first described in 1731 a case of femoral hernia, containing a non-inflamed appendix (1, 3).

EPIDEMIOLOGY

It is more common in childhood, given that inguinal hernia is, mainly, caused by a persistent patent processus vaginalis (PPV). Amyand's hernia cases have been recorded in every age, from neonates to elderly (4). Amyand's hernia corresponds to 2% of all appendectomies, during neonatal period and infancy (5). It is, understandably, more frequent in males, due to the greater incidence of inguinal hernia, and right-sided (4). A left sided Amyand's hernia is usually the consequence of the mobile cecum syndrome and presence of sizeable appendix. However, in theoretical basis, it can be present on a background of situs inversus or malrotation (2, 3, 5, 6, 7). In a review of 30 cases, 3 out of 30 were left-sided (8). According to Kinoo et al., only 15 left-sided Amyand's hernia cases were reported, until 2013 (2). Nicola et al. and Mahajan et al. described cases, in which Amyand's hernia was accompanied with the bladder, ovarian, fallopian tube, omentum or a Meckel diverticulum. Cecum is the organ that is most frequently contained within hernia sac (9, 10). Additionally, in cases of complete appendiceal protrusion within the sac, at least a part of the cecum protrudes, as well.

PATHOPHYSIOLOGY

Amyand's hernia occurs in 1% (0.19–1.7%) of all inguinal hernia cases (2, 3, 6, 11). In 0.13% of all cases, the appendix is inflamed. It should be noted that appendiceal perforation leads to a dramatic increase of the mortality rate (15–30%), due to severe abdominal sepsis (2, 3, 6, 12).

The incidence of acute appendicitis in the general population is 8%, whereas- as mentioned above - incidence of appendicitis present in an inguinal hernia is reported to be 0.1% (12, 13). The exact mechanism of appendicitis, within an inguinal hernia is not fully understood (5). After a thorough review of the existing literature, some opinions are reported below:

- (1) Incarceration and, subsequently, inflammation of the appendix (14, 15).
- (2) The presence of the appendix within the hernia sac predisposes for the development of adhesions between its serous membrane and the hernia sac, resulting in an irreducible hernia, susceptible to injury (6, 16).
- (3) The contraction of anterolateral abdominal muscles leads to an increase in intra-abdominal pressure, causing

compression and functional obstruction of the prolapsed appendix (17).

(4) Inflammatory swelling of the appendix may be the beginning of a vicious cycle. Thus, Amyand's hernia becomes irreducible, accentuating the swelling due to venous stasis and causing an impaired microcirculation of the appendix wall, resulting in bacterial overgrowth and translocation (11, 12).

CLINICAL PRESENTATION

This entity is usually asymptomatic, presenting with the typical symptoms of inguinal hernia in childhood (reducible - usually, automatically - bulge of the groin with local mild discomfort). In very rare cases, incarceration and obstruction of the appendix may be induced, resulting in acute appendicitis (18, 19). Given that the inflamed appendix is contained within the hernia sac, the symptoms of the appendicitis, in this case, are those of an irreducible or incarcerated inguinal hernia or, occasionally, of an acute scrotum ipsilaterally with the inguinal hernia, with accompanying symptoms such as pain in the right lower quadrant of the abdomen, anorexia, nausea and vomiting (20, 21, 22). During physical examination, common findings include a painful, irreducible bulge in the groin area, accompanied with swelling of the overlying tissue and excessive redness of the overlying skin. Typically, McBurney sign is absent in those patients (23, 24). Differential diagnosis should include hydrocele, testicular torsion, inguinal lymphadenitis and epididymo-orchitis (10).

DIAGNOSIS

In most cases, Amyand's hernia is diagnosed intra-operatively (5, 6, 25). Sharma et al. treated 18 patients with Amyand's hernia, while no patient was diagnosed pre-operatively (6, 26). Cankormaz et al. treated 12 neonates and infants (median age = 40 days) with Amyand's hernia, making the diagnosis pre-operatively in one out of twelve cases (22). Weber et al. performed a retrospective study of 60 Amyand's hernia cases, treated over 12 years, out of which the hernia was diagnosed in only one of them (14).

In certain cases, the performance of imaging -such as ultrasound or computed tomography (CT) could provide useful information substantial for preoperative diagnosis (6, 27). Okur et al. studied 21 Amyand's hernia cases, performing a preoperative ultrasound in 12/21 cases (57.1%) and diagnosing the hernia in 9/12 (75%) of them (11).

Most surgeons do not recommend imaging examination in the context of preoperative evaluation, in order to proceed with surgical repair of an inguinal hernia, especially when there is indication of prompt therapeutic intervention. We believe that a symptomatic incarcerated or difficultly reducible inguinal hernia should be investigated via imaging studies, aiming at increasing the number of complicated Amyand's hernia cases being preoperatively diagnosed.

The most significant ultrasound finding is the presence of a non-compressible tubular structure within the hernia sac. In case of appendicitis, additional features include wall thickening and hyperemia (20, 28).

The primary CT signs considered as pathognomonic for Amyand's hernia are a blind ending tubular structure inside the hernia sac, arising from the base of the caecum, wall thickening, hyperemia and periappendiceal fat stranding (12, 20).

THERAPEUTIC STRATEGY

Losanoff and Basson proposed a classification for Amyand's hernia, setting a therapeutic framework (Table 1) (20, 29, 30, 31).

Tab. 1: Losanoff and Basson classification of Amyand's hernia.

Classification	Description	Management
Type 1	Normal appendix in an inguinal hernia	Hernia reduction, mesh replacement
Type 2	Acute appendicitis in an inguinal hernia with no abdominal sepsis	Appendectomy, primary no prosthetics hernia repair
Type 3	Acute appendicitis in an inguinal hernia with abdominal and abdominal wall sepsis	Laparotomy, appendectomy, and primary no prosthetic hernia repair
Type 4	Acute appendicitis in an inguinal hernia with abdominal concomitant pathology	Same as type 3 plus management of concomitant disease

Tab. 2: Classification of Amyand hernia after Rikki modification.

Classification	Description	Management
Type 1	Normal appendix in an inguinal hernia	Hernia reduction, mesh replacement
Type 2	Acute appendicitis in an inguinal hernia with no abdominal sepsis	Appendectomy, primary no prosthetics hernia repair
Type 3	Acute appendicitis in an inguinal hernia with peritoneal and/or abdominal wall sepsis	Laparotomy, appendectomy, and primary no prosthetic hernia repair
Type 4	Acute appendicitis in an inguinal hernia with abdominal concomitant pathology	Same as type 3 plus management of concomitant disease
Type 5a	Normal appendix within an incisional hernia	Hernia reduction, primary repair of hernia including mesh replacement
Type 5b	Acute appendicitis within an incisional hernia without peritonitis	Appendectomy through hernia, primary closure of the aponeurotic gap, no prosthetics hernia repair
Type 5c	Acute appendicitis within an incisional hernia with peritonitis or abdominal wall sepsis or in relation to previous surgery.	Management as type 4

Singal et al. refer to the modification of the Losanoff and Basson classification of Amyand's hernia, also known as Rikki modification. A fifth type of Amyand's hernia is added on the latter classification, referred as an incisional hernia through which the vermiform appendix protrudes. This type is divided into three subtypes, 5a, 5b and 5c (Table 2) (30).

As a general rule, in case of a non-inflamed appendix, the patient undergoes hernia repair without appendectomy (12, 19, 22, 31). Researchers sharing this opinion believe that this approach could decrease postoperative complications, as a clean surgery is not converted to a clean-contaminated one. Besides, the appendix could be used, in the future, for replacement of the extra-hepatic biliary tract, urinary diversion or appendicostomy (Malone procedure) (9, 33). Furthermore, during appendectomy, surgical manipulations in the base of the caecum could increase the recurrence rate of the inguinal hernia, due to detachment in the deep inguinal ring (32). It should be noted that surgical manipulations involving the appendix could trigger secondary acute inflammation (32, 33). This - theoretical - possibility is minimized, when the procedure is performed laparoscopically (9, 33). Shaknovsky et al. refer to the successful treatment of an adult patient with Amyand's hernia type I, after application of Robotic platform Da Vinci Surgical System' 3D HD imaging (34).

Exception to this rule is an non-inflamed appendix contained in a left-sided Amyand's hernia, where preventive appendectomy is recommended, as, in case of a future appendicitis, there is a high risk of false or delayed diagnosis or even resistive surgical procedure (8, 12, 35).

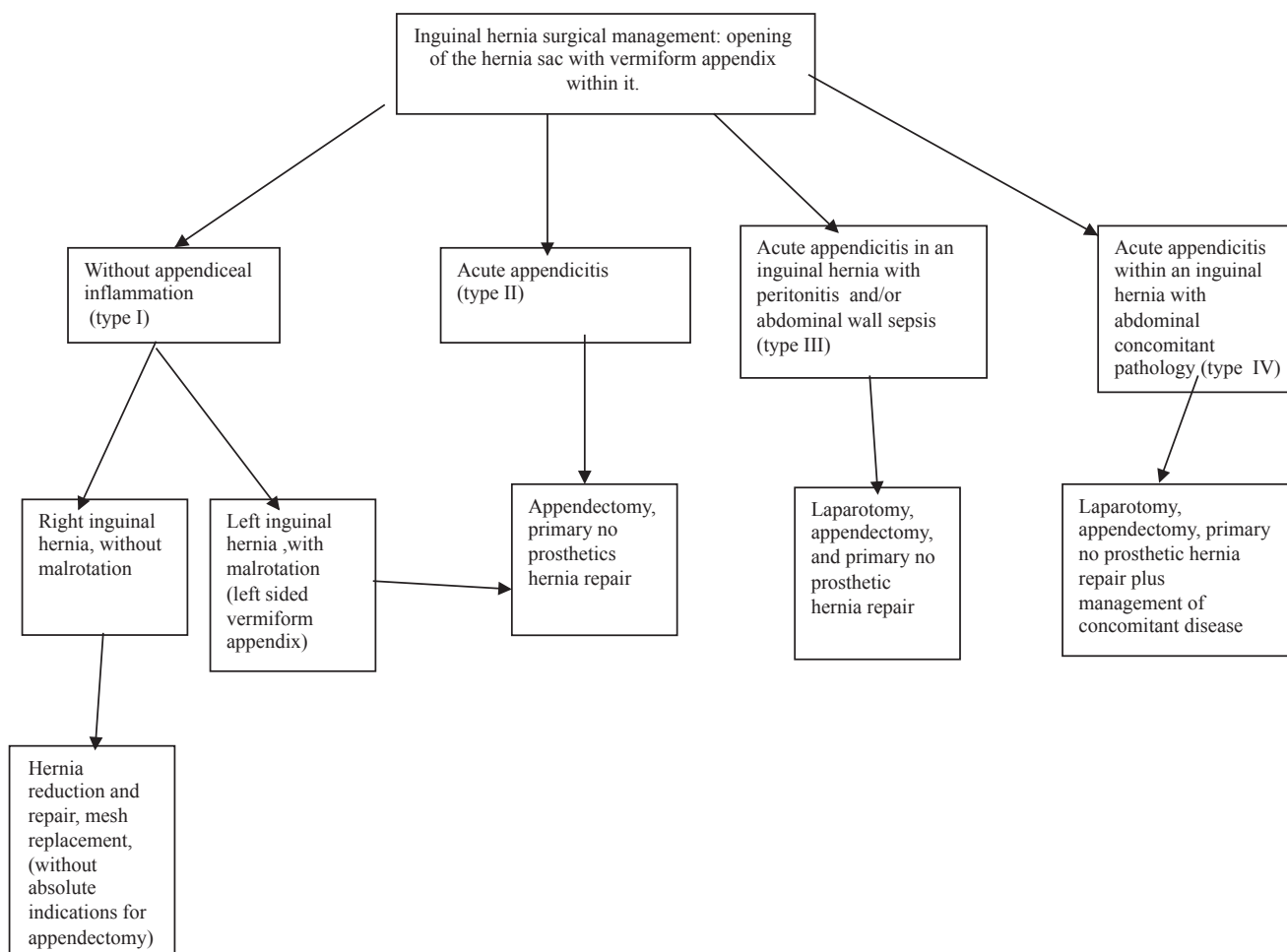
We believe that algorithmic approach of Amyand's hernia, as described in schema 1, is a safe guide as for choice of the appropriate therapeutic strategy (Schema 1).

ACKNOWLEDGEMENTS, FUNDING AND DISCLOSURES

All the authors contributed equally to the writing of this short review article. None of the contributing authors have any conflict of interest, including specific financial interests or relationships and affiliations relevant to the subject matter or materials discussed in the manuscript.

REFERENCES

1. Amyand C. Of an inguinal rupture, with a pin in the appendix coeci, incrusted with stone, and some observations on wounds in the guts. *Philosophical Transactions* 1835; 39: 1735-6.
2. Mewa Kinoo S, Aboobakar MR, Sigh B. Amyand's hernia: A serendipitous diagnosis. *Case Report in Surg* Volume 2013; Article ID 125095.
3. Morales-Cardenas A, Ploneda-Valencia CF, Sainz-Escarrega VH, et al. Amyand hernia: Case report and review of the literature. *Ann Med Surg* 2015; 4:113-5.
4. Ivashuk G, Cesmebasi A, Sorenson EP, Blaak C, Loukas M, Tubbs SR. Amyand's hernia: a review. *Med Sci Monit* 2014; 28(20): 140-6.
5. Gupta S, Sharma R, Kaushik R. Left sided Amyand's Hernia. *Singapore Med J* 2005; 46(8): 424-5.
6. Hiatt JR, Hiatt N. Amyand's Hernia. *N Engl J Med* 1988; 318(21): 1402.
7. Losanoff JE, Basson MD. Amyand Hernia: what lies beneath a proposed classification scheme to determine management. *Am Surg* 2007; 73(12): 1288-90.



Schema 1: Algorithmic therapeutic approach of Amyand's hernia.

8. Holmes M, Ee M, Fenton E, Jones N. Left Amyand's hernia in children: method, management and myth. *J Pediatr Child Health* 2013; 49(9): 789-90.
9. Nikola SM. Hernia de Amyand: presentacion de un caso y revision de la literature. *Rev Chil Cirugia* 2007; 59(2): 142-4.
10. Mahajan A, Pawar P, Luther A, Haque P. Right sided Amyand's hernia: a rare case report. *Int Surg J* 2014; 1(1): 43-4.
11. Okur MH, Karacay S, Uygun I, Topc K, et al. Amyand's hernias in childhood (a report on 21 patients): a single-centre experience. *Pediatr Surg Int* 2013; 29(6): 571-4.
12. Singhal S, Singhal A, Singh Negi S, et al. Amyand's hernia: rare presentation of a common ailment. *Case Reports in Gastrointestinal Medicine* 2015 Volume 2015; Article ID 629127.
13. Sengul I, Sengul D, Aribas D. An elective detection of an Amyand's hernia with an adhesive caecum to the sac: report of a rare case. *North Am J Med Sciences* 2011; 3(8): 391-3.
14. Weber RV, Hunt ZC, Kral JC. Amyand's hernia. Etiologic and therapeutic implications of two complications. *Surg Rounds* 1999; 22: 552-6.
15. Ash L, Hatem S, Ramirez GA, Veniero J. Amyand's hernia: a case report of prospective ct diagnosis in the emergency department. *Emerg Radiol* 2005; 11(4): 231-2.
16. Abu-Dalu J, Urca I. Incarcerated inguinal hernia with a perforated appendix and periappendicular abscess: report of a case. *Dis Colon Rectum* 1972; 15(6): 464-5.
17. Solecki R, Matyja A, Milanowski W. Amyand's hernia: a report of two cases. *Hernia* 2003; 7(1): 50-1.
18. Hotiana MM, Kundu S, Ahmad I. Complicated inguinal hernia of Amyand. *South Med J*. 2007; 100(4): 411.
19. Nigri G, Costa G, Valabrega S, et al. A rare presentation of Amyand's hernia. Case report and review of the literature. *Minerva Chir* 2008; 63(2): 169-74.
20. Okur MH, Arslan MA, Zeytun H, Otcu S. Amyand's hernia complicated with acute appendicitis: A case report and literature review. *Ped Urol Case Rep* 2015; 2(4): 7-12.
21. Quartey B, Ugochukwu O, Kuehn R, Ospina K. Incarcerated recurrent Amyand's hernia. *J Emerg Trauma Shock* 2012; 5(4): 344-6.
22. Cankorkmaz L, Ozer H, Guney C, et al. Amyand's hernia in the children: a single center experience. *Surgery* 2010; 147(1): 140-3.
23. Fernando J, Leelaranta S. Amyand's hernia. *Ceylon Med J* 2002; 2: Article 71.
24. Laermans S, Aerts P, De Man R. Amyand's hernia: inguinal hernia with acute appendicitis. *J de Belge de Radiologie* 2007; 90(6): 524-5.
25. Green J, Gutwein LG. Amyand's hernia: a rare inguinal hernia. *JSCR* 2013; 9: 140-6.
26. Sharma H, Gupta A, Shekhawat NS, Memon B, Memon MA. Amyand's hernia: a report of 18 consecutive patients over a 15-year period. *Hernia* 2007; 11(1): 31-5.
27. Michalinos A, Moris D, Vernadakis S. Amyand's hernia: a review. *Am J Surg* 2014; 207(6): 989-95.
28. Tsang WK, Lee KL, Tam KF, et al. Acute appendicitis complicating Amyand's hernia: imaging features and literature review. *Hong Kong Med J* 2014; 20(3): 255-7.
29. Dange A, Gireboinwad S. A rare case of Amyand's hernia presenting in a 3-year-old male child. *Indian J Surg* 2013; 75(4): 332-3.
30. Singal R, Mittal A, Gupta S, Sahu P, Sekhon MS. An incarcerated appendix: report of three cases and a review of the literature. *Hernia* 2012; 16(1): 91-7.
31. Jabloun A, Bouthour H, Bustame S, et al. Amyand's hernia with appendicitis in the children: A delayed diagnosis. *J Pediatr Surg Case Reports* 2016; 13: 6-7.
32. Livaditi E, Mavridis G, Christopoulos Geroulanos G. Amyand's hernia in premature neonates: report of two cases. *Hernia* 2007; 11(6): 547-9.
33. Ofili OP. Spontaneous appendectomy and inguinal herniorrhaphy could be beneficial? *Ethiopian Med J* 1991; 29(1): 37-8.
34. Shaknovsky TJ, Sabido F, Shaikh D, Rosen P. Robotic repair of Amyand's hernia; a case report. *J Case Rep Images Surg* 2016; 2: 92-96.
35. Johari HG, Paydar S, Zeraatian S, Davani N, et al. Left sided Amyand hernia. *Annals of Saudi Med* 2009; 29(4): 321-2.