

Abnormal Origin and Course of the Accessory Phrenic Nerve: Case Report

George Paraskevas^{1,*}, Konstantinos Koutsouflianiotis¹, Panagiotis Kitsoulis², Ioannis Spyridakis¹

¹ Department of Anatomy, Faculty of Medicine, Aristotle University of Thessaloniki, Thessaloniki, Greece

² Department of Anatomy, Histology and Embryology, Faculty of Medicine, University of Ioannina, Ioannina, Greece

* Corresponding author: Department of Anatomy, Faculty of Medicine, Aristotle University of Thessaloniki, Thessaloniki, Greece, PO Box: 300, Postal Code: 54124; e-mail: g_paraskevas@yahoo.gr

Summary: In the current cadaveric study an unusual sizeable accessory phrenic nerve (APN) was encountered emerging from the trunk of the supraclavicular nerves and forming a triangular loop that was anastomosing with the phrenic nerve. That neural loop surrounded the superficial cervical artery which displayed a spiral course. The form of a triangular loop of APN involving the aforementioned artery and originating from the supraclavicular nerve to the best of our knowledge has not been documented previously in the literature. The variable morphological features of the APN along with its clinical applications are briefly discussed.

Keywords: Phrenic nerve; Accessory; Variation; Applications

Introduction

The accessory phrenic nerve (APN) as it is well known constitutes a slender branch arising from the fifth cervical ventral ramus via the nerve to the subclavius, lying lateral to the phrenic nerve (PN) and descending posterior or sometimes anterior to the subclavian vein. Ultimately the APN joins the PN usually near the first rib or beyond the base of the neck inside the thoracic cavity (1, 2). The APN's incidence displays a great variability ranging between 17.6% in German population as reported by Felix in 1922 (3) and 75% (4). Apart from APN's main origin from the nerve to subclavius it can take its origin from other sources such as ansa cervicalis, nerve to sternothyroid, supraclavicular nerve, roots of brachial plexus, spinal accessory or even hypoglossal nerve (5, 6). APN constitutes a relatively neglected neural structure, since much greater attention has been paid to PN's anatomy. The APN is at risk after thoracic surgical procedures, subclavian vessel catheterization, and supraclavicular brachial plexus blocks.

In the current study, we present a very rare variant of the APN, that combines a rare origin from the supraclavicular nerve and an unusual loop around the superficial cervical artery.

Case report

During routine gross anatomy course dissection, we came across a very rare variant of a neural loop involving an arterial trunk in the cervical region of a 75-year-old formalin-fixed male cadaver, whose cause of death was not related to the current study. After careful removal of the skin, cervical fasciae, and sternocleidomastoid muscle, we

encountered an unusual nerve arising from the trunk of the left supraclavicular nerves just after it emerged from the posterior border of the left sternocleidomastoid muscle at a distance of 0.9 cm from Erb's point. Erb originally described this point as "a circumscribed point about 2–3 cm above the clavicle somewhat outside of the posterior border of the sternomastoid muscle" (7). However, we utilized as a landmark the "punctum nervosum" that is situated ap-

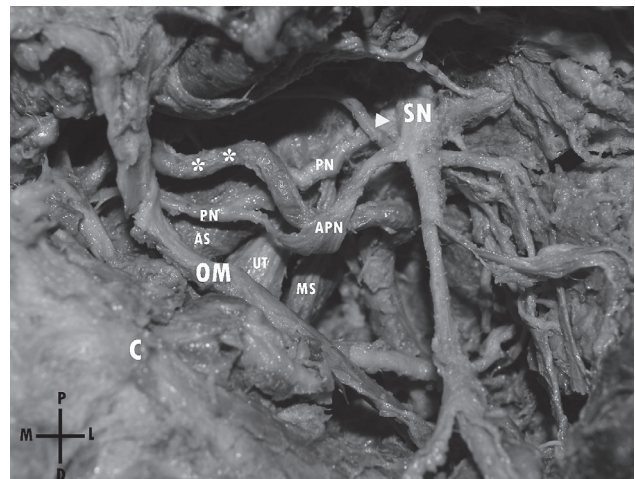


Fig. 1: Photograph of the left posterior triangle of the neck, where an atypical loop is observed interconnecting the accessory phrenic nerve (APN) with the ipsilateral phrenic nerve (PN). The APN/PN loop is seen surrounding the left superficial cervical artery (asterisks). (SN: supraclavicular nerve, OM: omohyoid muscle, C: clavicle, AS: Anterior scalene muscle, MS: Middle scalene muscle, UT: upper trunk of brachial plexus, P: proximal, D: distal, M: medial, L: lateral).

proximately at the midpoint of the posterior border of the sternocleidomastoid muscle (8). A sizable APN was identified here, which after a short course of 1.6 cm divided into a proximal ascending and a distal descending branch both of which communicated with the left PN proximal to the intermediate tendon of the ipsilateral omohyoid muscle. This triangular neural loop surrounded the left superficial cervical artery (Fig. 1). No other associated anatomical variations or scars from previous surgical procedures were present. The origin, course, and morphology of this neural APN/PN loop and its relationship to the surrounding anatomical structures were photographed during the dissection.

Discussion

The APN is an inconstant nerve with a highly variable incidence. Its frequency in cadaveric studies was 61.8–65% (from Aycock et al as cited by Kelley) (5, 9). In other studies the incidence ranged from 2.63% (10) to 80.9% (5, 6, 10, 11). Given these figures APN could be regarded as a constant neural element and not a variant (5). A crucial point is the precise APN's definition. Loukas et al decided that all nerves contributing to the PN after it had crossed the anterior scalene muscle would be considered as APN (5). According to Hollinshead's textbook of Anatomy when two parts of the PN exist coursing parallel to each other for a variable distance on the anterior scalene muscle, usually the lower is called APN (12). Banneheka identified the additional contributions to PN passing anterior to the subclavian vein (in 28.7%) as APN, whereas those found passing posterior to the subclavian vein were termed secondary PNs (in 19.8%) (13). As regards its origin, APN usually arises from the nerve to subclavius (45.8–60.6%) and the ansa cervicalis (12.1–16.6%) (5, 6, 14). The APN may also originate from the upper trunk of the brachial plexus, the nerve to sternohyoid, C4 root or the supraclavicular nerve (4–16.6%) (5, 6). Uncommon origins include the hypoglossal, spinal accessory and vagus nerves (5, 14).

APN usually joins the PN within the thorax (67.7%) and not at the root of the neck (32.3%) as is usually reported (5). The loop between the APN and PN may include a vessel, such as the internal thoracic artery, which may complicate harvesting of that artery during coronary artery bypass grafting. Such a loop was detected in 38.4% by Loukas et al (5), whilst Nayak et al found none (6). An APN/PN loop including the subclavian vein was observed in 34.4–45.5% of cases (5, 6). This loop can be damaged during subclavian vein catheterization. An APN/PN loop was observed involving the subclavian artery in 1.11% of cases (6).

An APN/PN loop including the superficial cervical artery as noted in the current study has not documented in the literature to the best of our knowledge. The formation of a neural loop including an artery is an uncommonly detected condition. It has been postulated that with the establishment of the muscular system during embryological development, the nerve pattern becomes fixed and does not adjust itself to

the more variable arteries when they tend to revert to their earlier primate positions. This constitutes an explanation for the condition where a nerve is perforated by an artery (15).

Although PN's lesion during subclavian vein catheterization is well known and established in the literature (16), APN could be damaged during subclavian vein's cannulation especially in cases where it is situated anterior to that vein. Moreover, the APN is vulnerable during supraclavicular exposures performed for thoracic outlet syndrome. It has been reported that permanent or transient diaphragmatic dysfunction after scalenectomy could be due not only to PN's injury but to APN's injury as well (17). The APN's presence can explain the preservation of forced vital capacity even in patients after a supraclavicular block of the brachial plexus (18). The presence of an APN may also explain why bilateral PNs transection may be compatible with life (19).

Conclusion

The APN may be less of a variant and more of a constant neural structure. A rare origin from the supraclavicular nerve trunk encircling the superficial cervical artery is described.

References

- Berry M, Bannister LH, Standring SM, et al. Nervous System. In: Williams PL, eds. *Gray's Anatomy*. Edinburgh: Churchill Livingstone, 1995: 1265–6.
- Basmajian JV. *Grant's Method of Anatomy*. 8th ed. Baltimore: Williams and Wilkins Co, 1971: 560.
- Kikuchi T. A contribution to the morphology of the ansa cervicalis and the phrenic nerve. *Kaibogaku Zasshi* 1979; 45: 242–81.
- Bergman RA, Afifi AK, Miyachi R, et al. *Illustrated Encyclopedia of Human Anatomic Variation: Opus III: Nervous System: Plexuses, Phrenic Nerve*. <http://www.anatomyatlases.org>. Accessed on 30 August 2015.
- Loukas M, Kinsella CR, Louis RG, Gandhi S, Curry B. Surgical anatomy of the accessory phrenic nerve. *Ann Thorac Surg* 2006; 82: 1870–5.
- Nayak SR, Krishnamurthy A, Prabhu LV, et al. Incidence of accessory phrenic nerve and its clinical significance: a cadaveric study. *Acta Med* 2008; 51(3): 181–4.
- Erb W. *Handbook of Electro-Therapeutics* (translation: L Putzel). New York: William Wood and Co, 1883: 122–4.
- Frank DK, Wenk E, Stern JC, Gottlieb RD, Moscatello AL. A cadaveric study of the motor nerves to the levator scapulae muscle. *Otolaryngol Head Neck Surg* 1997; 117: 671–80.
- Kelley WO. Phrenic nerve paralysis; special consideration of the accessory phrenic nerve. *J Thorac Surg* 1950; 19: 923–8.
- Dayal S, Ky M. The variations in the roots of origin of the phrenic nerve. *JMGIMS* 2009; 14(2): 24–7.
- Fazan VPS, Amadeu ADS, Caleffi AL, Filho OAR. Brachial plexus variations in its formation and main branches. *Acta Cir Bras* 2003; 18(suppl. 5): 14–8.
- Rosse C, Gaddum-Rose P. *Hollinshead's Textbook of Anatomy*. 5th ed. Philadelphia: Lippincott-Raven, 1997: 720–1.
- Banneheka S. Morphological study of the ansa cervicalis and the phrenic nerve. *Anat Sci Int* 2008; 83: 31–44.
- Yano K. Zur Anatomie und Histologie des Nervus phrenicus und soggenanten Nebenphrenicus, nebst Bemerkungen uber ihre Verbindung mit Sympathicus. *Folia Anat Jpn* 1925; 6: 247–90.
- Miller RA. Observations upon the arrangement of the axillary artery and brachial plexus. *Am J Anat* 1939; 64: 143–63.
- Paraskevas GK, Raikos A, Chouliaras K, Papaziogas B. Variable anatomical relationship of phrenic nerve and subclavian vein: clinical implication for subclavian vein catheterization. *Br J Anaesth* 2011; 106(3): 348–51.
- Sharma MS, Loukas M, Spinner RJ. Accessory phrenic nerve: a rarely discussed common variation with clinical implications. *Clin Anat* 2011; 24: 671–3.
- Bigeleisen PE. Anatomical variations of the phrenic nerve and its clinical implication for supraclavicular block. *Br J Anaesth* 2003; 91(6): 916–7.
- Vilensky JA. "C3, C4, C5, keep you alive" or do they? *Clin Anat* 2006; 19: 130–1.

Received: 02/09/2015

Accepted: 16/03/2016