

# Treatment of Chondral Defect of the Knee Joint – Current Methods, Possibilities of Using Cultured Mesenchymal Stem Cells

---

Libor Prokeš<sup>1,\*</sup>, Tomáš Kučera<sup>1</sup>

## ABSTRACT

Cartilage damage is caused by degenerative process and also by trauma, microtrauma or as a consequence of avascular necrosis. The damage may be focal or diffuse over a larger area. Because of the limited healing potential, treatment of articular cartilage injuries is problematic. The choice of surgical treatment depends on several factors: the size, depth and location of the defect, the age of the patient, the desired activity, associated changes and the possibility of postoperative rehabilitation. Finding an appropriate method of treatment for chondral defects with a reliable long-term outcome is difficult. The most common, clinically proven and used surgical techniques include abrasive chondroplasty, marrow stimulating techniques, transplantation procedures or a combination of methods. The possibility of introducing new methods in the form of the application of cultured mesenchymal stem cells represents a significant advance in the field of regenerative medicine. Their use is safe and effective.

## KEYWORDS

chondral defect; mesenchymal stem cells; 3D carrier; hyaline cartilage

## AUTHOR AFFILIATIONS

<sup>1</sup> Department of Orthopedy, University Hospital and Charles University, Faculty of Medicine, Hradec Králové, Czech Republic

\* Corresponding author: Department of Orthopedy, University Hospital and Charles University, Faculty of Medicine, Sokolská 581, 500 05 Hradec Králové, Czech Republic; libor.prokes@fnhk.cz

Received: 9 February 2025

Accepted: 26 March 2025

Published online: 16 June 2025

---

Acta Medica (Hradec Králové) 2025; 68(1): 8–13

<https://doi.org/10.14712/18059694.2025.12>

© 2025 The Authors. This is an open-access article distributed under the terms of the Creative Commons Attribution License (<http://creativecommons.org/licenses/by/4.0>), which permits unrestricted use, distribution, and reproduction in any medium, provided the original author and source are credited.

## INTRODUCTION

Cartilage is a connective tissue composed of chondrocytes and extracellular matrix with collagen fibrils, it has a firm consistency and its property is compressive elasticity. It responds to pressure by deforming its shape, which returns to its original form when the pressure subsides. The proteoglycans contained in the extracellular matrix and the collagen fibrils are responsible for this elasticity. The cartilage is vascular-free and nutrition is provided by diffusion through the intercellular matrix. Cartilage function depends on the quantitative and qualitative ratio of proteoglycans and their glycosaminoglycan (GAG) chains and the arrangement of collagen fibrils. Articular cartilage acts as a shock absorber and ensures an even distribution of shock to the surface (1).

Cartilage damage is caused by degenerative process and also by trauma, microtrauma or as a consequence of avascular necrosis. The damage may be focal or diffuse over a larger area. Degenerative changes in cartilage are characterized by damage to collagen fibres and loss of GAG chains; the ratio of individual particles changes with an increase in water content. Due to its limited regenerative capacity, any damage to cartilage is a serious problem. Its main disadvantage is the limited ability of the internal repair processes of its own chondrocytes, which are rigidly fixed in the protein matrix. Therefore, they cannot migrate to the injured area and participate in the repair process. Patients with a deep chondral defect suffer from pain, swelling and limitation of joint mobility. Untreated cartilaginous lesions gradually progress and lead to the development of premature arthrosis.

The aim of this thesis is to present current modern methods of treatment of post-traumatic and degenerative chondral defects with the possibility of using cultured bone marrow mesenchymal stem cells.

## IMAGING METHODS

### X-RAY IMAGE

Among the radiodiagnostic methods, the classical X-ray examination takes the leading position. However, normal hyaline cartilage is not contrasted on sciagraphic examination, and therefore we evaluate it indirectly by the spread of the articular cleft and the reaction of the surrounding bone (subchondral sclerotization, reactive bidding and the formation of osteophytes of the articular surfaces marginally). It is of major importance for the detection of osteochondral fragments.

### MAGNETIC RESONANCE

Magnetic resonance imaging holds a dominant position among the examination methods of articular cartilage pathologies. The development of examination techniques has optimized the display of cartilage morphology, its volumetry and now also the possibility of biochemical analysis. Due to its high resolution and spatial resolution, it is an ideal method for imaging the soft tissues of the joint and cartilage in its entirety, including the pathologies pre-

sent. Another advantage is the possibility of volumetric measurement of cartilage when assessing the progression of degenerative and inflammatory diseases or monitoring during therapy, both osteochondral graft attachment and medical therapy. Its indisputable advantage is that its non-invasiveness does not burden the patient. Another advantage of the newer MRI machines is the use of sequences with excellent resolution of cartilaginous tissue. According to the information available in the literature, the authors have the most experience and achieve good results in imaging chondral pathologies using proton density (PD), T2 Fast Spin Echo (T2 FSE) or Fast LowAngle-Shot (FLASH) sequences. Fat signal suppression sequences have become useful for imaging cartilage pathologies. PD and T2 FSE sequences are advantageous for visualizing damage to the middle and deep layers of cartilage, while the FLASH sequence is useful for visualizing superficial lesions (2, 3). Furthermore, the author's experience shows the usefulness of multiplanar imaging, which increases sensitivity and specificity in detecting chondral lesions (3–6). Newer methods such as T1rho and T2 mapping, Na<sup>+</sup> imaging or delayed cartilage saturation methods such as dGEMRIC (delayed Gadolinium-Enhanced) are gaining importance.

## TREATMENT OF CHONDRAL DEFECTS

Because of the limited healing potential, treatment of articular cartilage injuries is problematic. The choice of surgical treatment depends on several factors: the size, depth and location of the defect, the age of the patient, the activity required, associated changes and the possibility of postoperative rehabilitation. The development of arthroscopy with the development of more sophisticated instrumentation and with it new surgical techniques has been a shift in the possibility of treating and diagnosing not only chondral lesions. Finding a suitable method of treatment for chondral defects with reliable long-term results is difficult.

Joint resurfacing surgery alone may be without effect if the stability and axis of the limb is not restored. Failure of the limb axis leads to excessive pressure on the contact surface. This condition can be influenced by an appropriate type of osteotomy. The main aim of proximal tibial osteotomy is to improve the biomechanical aspects and biological properties of the joint. The horizontal positioning of the articular cleft and the correction of the mechanical axis by a slight re-alignment to valgus leads to a shift of the loading force from the damaged compartment to the undamaged one. The blood supply increases in the vicinity of the osteotomy and the rate of venostasis decreases in the damaged parts of the joint. The change in innervation is usually associated with a decrease in pain and indirectly with an increased range of motion in the joint. When the indication criteria and methodology are followed correctly, corrective osteotomy contributes to a reduction in pain and slows the progression of arthrosis (7). Regeneration of the hyaline cartilage of the medial compartment of the knee during "second look arthroscopy" has also been described by some authors (8). A less common deformity is valgus

deformity, for which a variation osteotomy of the lower femur is recommended. Similarly, joint stability is a concern. Surgical procedures that stabilize the knee joint, such as cruciate ligament repairs, reduce the risk of developing a cartilage defect and the risk of developing arthrosis.

The most common, clinically proven and used surgical techniques include abrasive chondroplasty, marrow stimulating techniques, transplantation procedures or a combination of methods. Abrasion chondroplasty (9) is used for chondral defects of smaller size (up to 2 cm<sup>2</sup>) or in patients with osteoarthritis. The cartilage defect is aligned and the unstable edges of the defect are removed to restore a smooth surface and remove the delaminated portions. Abrasion of the base of the chondral defect does not extend below the zone of calcified cartilage. Marrow-stimulating techniques consist of perforating the subchondral bone after removal of the remnants of damaged cartilage, allowing migration of undifferentiated mesenchymal stem cells into the defect area and vascular ingrowth. The first results of this technique were published by Pridie (10) in 1959, when he performed retreatments into the base of a cleaned defect and by Ficat (11). Over time, the designs were replaced by Steadman microfractures (12), which is currently the most widely used marrow-stimulating technique applicable not only in the knee (Fig. 1) but also in the shoulder (13) and hock (14) joints. A special curved chisel is used to break the subchondral bone 4 mm deep, 5 mm apart. The blood forms a fibrin plug at the base which starts to stimulate tissue healing. After 8–12 weeks, the primary plug transforms into fibrocartilaginous tissue. The fibrous reparative tissue formed is less robust and less resistant than the original hyaline type of cartilage. The effect of this surgical technique is less, especially in patients over 40 years of age and in those where the defect is larger than 2.5 cm<sup>2</sup>. In the long term, it does not prevent the onset and progression of degenerative changes. Another group of surgical procedures are transplantation procedures including implantation of cultured autologous chondrocytes, implantation of allogeneic osteochondral graft, transplantation of autologous osteochondral autografts (mosaicplasty) and implantation of structural supports. Transplantation of cultured autologous chondrocytes (ACI) is indicated for circumscribed deep chondral and osteochondral defects of the weight-bearing joints in younger patients ideally under 40 years of age within 3 cm<sup>2</sup>. The first results of the use of cultured chondrocytes were published by Peterson in 1984 (15). In 1994, Brittberg (16) published the first results of implantation of a suspension of cultured chondrocytes fixed with a periosteal flap sutured to the articular surface. The results of the ACI method were very good, yet this method had its drawbacks in the form of a two-stage procedure, laborious suturing of the periosteal flap, damage or loosening of the flap with spillage of the suspension, or hypertrophy of the flap. Therefore, new fixation options have been gradually developed with the emergence of new generations of carriers (tissue glue, collagen membranes, hyaluronic acid esters, polylactide). The carrier must be biocompatible and biodegradable and must meet the conditions of good adhesion of chondrocytes with their dispersion in different polymer matrices already during in vitro production. This third-generation ACI technique, referred

to as MACI (Matrix Induced Autologous Chondrocytes Implantation), has spread rapidly with very good results (17). Clinically used implants include polylactide acid polymer carriers (BioSeed-C), hyaluronic acid (Hyalograft-C) and autologous chondrocytes fixed in fibrin (Chondrograft). The results of the histological examination showed the formation of a mixture of connective and hyaline cartilage, collagen type II and proteoglycans. The resulting tissue is softer, well integrated with the subchondral bone. Stiffness tests lead to the conclusion that it is a regenerate of connective cartilage. Despite this fact, good medium-term clinical results are achieved, with a significant reduction in knee pain within one year and an improvement in joint function. Another method is the transplantation of autologous osteochondral grafts (mosaicplasty) described by Hangody (18, 19), designed to treat defects of 2–3 cm<sup>2</sup>. The principle is to take cylindrical osteochondral blocks from the nonload zone of the joint and transfer them to the defect site after preparation of the bone bed (Fig. 2). The bone component integrates well with the surrounding bone. Hyaline cartilage maintains its properties and adds congruence to the articular surface. The defect is 70% covered by hyaline cartilage, with connective tissue between the blocks. The disadvantage of mosaicplasty is the transfer of tissue that has different biomechanical properties to a site with different load requirements. Another disadvantage is the risk of healing failure at the donor site, referred to in English literature as “donor site morbidity”. In mosaic plastics, it is reported that up to 50% of patients have non-specific joint discomfort from the donor site. This could be eliminated by sizing the harvest block below the so-called critical defect size of 7 mm. Ligamentous cartilage always develops at the harvest zone. With the correct surgical procedure, the method works very well, it is a one-time and economically inexpensive method. An alternative to this method is the implantation of freshly frozen osteochondral allografts. Allogeneic grafts are mainly used to treat large osteochondral defects (6 to 8 cm<sup>2</sup> in diameter) for indications of traumatic cartilage lesions, osteonecrosis or osteochondrosis dissecans. The disadvantages of this method are the risk of an immune reaction to the graft and the risk of disease transmission to the recipient. Currently, the most popular method is the combination of abrasive techniques with the implantation of biocompatible, bioconductive materials, which are in liquid, gel or solid cross-linked polymer form (3D carriers). The essence of the AMIC (Autologous Matrix-Induced Chondrogenesis) technique is to implant a carrier that promotes the ingrowth of mesenchymal stem cells and their differentiation into a chondrogenic line after microfracture into the base of the defect, thereby promoting the formation of new cartilaginous tissue (20, 21). The biomaterial forms a hemostatic barrier, therefore no bleeding into the joint cavity occurs. The implant is resorbed within approximately 40–60 days after implantation. It is usually fixed to the subchondral bone using biodegradable nails or tissue glue. AMIC therapy has given better results than microfracture alone in prospective studies (22). The AMIC technique is safe, functional, and effective for small to moderate (2 × 3 cm) cartilage defects, particularly in the knee. Some authors use the method for defects up to 8 cm<sup>2</sup> (23). The most commonly used polymeric materials include



Chondrotissue® (polyglycolic acid-based implant), Hyalofast® (esterified hyaluronic acid), Novocart® (type I collagen). Another option is artificial implants functioning as inserts (hydroxyapatite crystals with type I collagen).

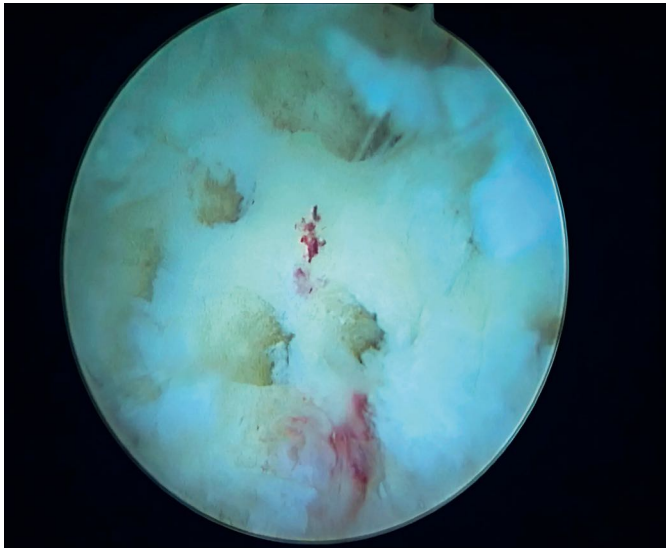


Fig. 1 Microfracture Steadman.

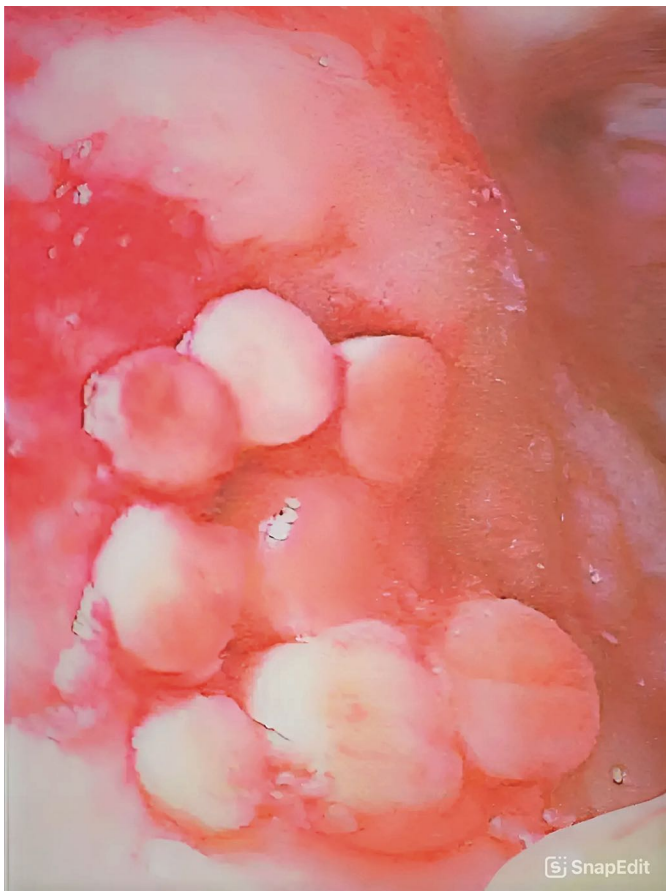

Fig. 2 Mosaicplasty.

We are currently conducting a clinical study in our clinic to help us refine this method using cultured mesenchymal stem cells. Mesenchymal Stem Cells (MSC) are multipotent stem cells that have the ability to differentiate

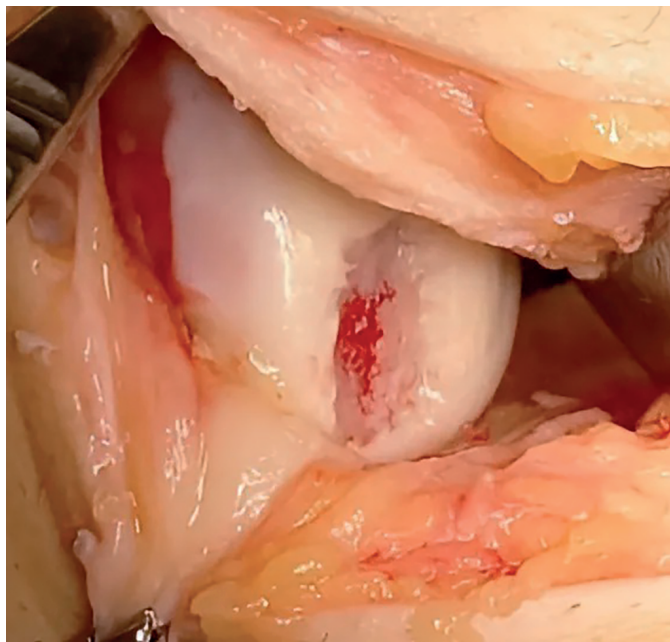
into different cell types such as osteocytes, chondrocytes and adipocytes. MSCs are naturally found in various tissues, including bone marrow (the main source of MSCs), adipose tissue, synovial fluid etc. The basic properties of stem cells include:

1. Multipotency: the ability to differentiate into different cell types.
2. Immunomodulatory properties: MSCs can regulate the immune response, which is important for the treatment of inflammatory diseases.
3. Paracrine effect: they produce various bioactive molecules that promote tissue regeneration and angiogenesis (formation of new blood vessels).
4. Easy insulation and expansion: MSC can be easily obtained and propagated under laboratory conditions.

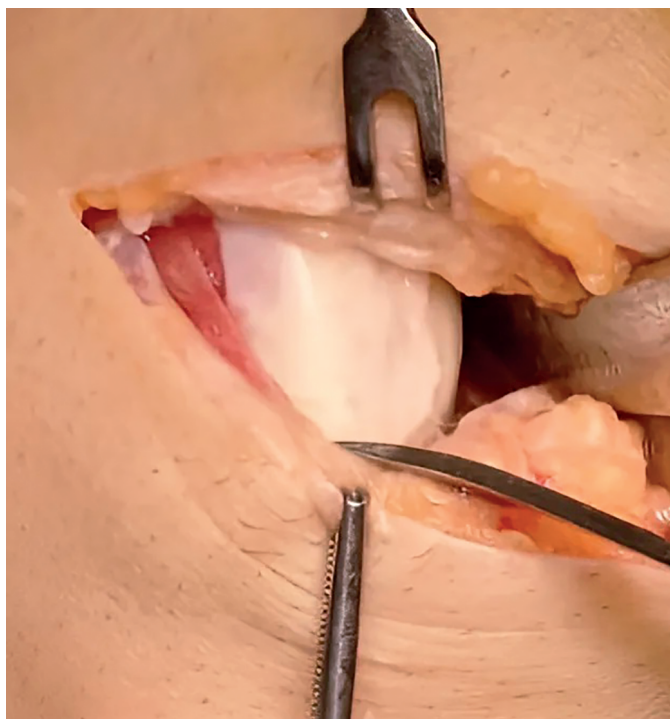
Mesenchymal stem cells have been extensively researched in the field of regenerative medicine due to their ability to repair damaged tissues. In recent years, MSC research has focused on their use in clinical practice. Many clinical trials are underway to investigate their safety and efficacy in various diseases. Importantly for use in clinical practice, they are not teratogenic and can be used both autologous and allogeneic. Mesenchymal stem cells have achieved good results in *in vitro* tests (24), in animal models (25) and in early clinical trials in humans (26, 27). Bone marrow-derived stem cells have been shown to have a higher capacity for chondrogenic differentiation than adipose tissue-derived stem cells (28). Bone marrow-derived MSCs also produce significantly more type II collagen and glycosaminoglycan than adipose-derived stem cells (29). Although the results are promising, MSC therapy still faces challenges such as standardizing their isolation and culture, identifying the ideal dose, and long-term safety. At our institution, we obtain MSCs from the hip flap by biopsy needle harvesting of 26–30 ml of aspirate under local anesthesia 3–4 weeks before surgery. After isolation and expansion of the MSCs, the surgical procedure is performed, which consists of a mini-arthrotomy, removal of the malar cartilage remnants, alignment of the edges of the defect and treatment of its fundus with Priedi flaps (Fig. 3). Subsequently, a cell suspension - Bi-Cure®orthoMSCp is uniformly applied to the 3D Hyalofast carrier in the operating room before final treatment of the carrier, resulting in a concentration of  $0.98 (\pm 0.19) \times 10^6$  cells per  $\text{cm}^2$  of carrier surface. After the gelation phase, the carrier is adjusted to the desired size and shape. After preparation, it is implanted into the defect site in one or 2 layers and fixed using Tisseel fibrin sealant (Fig. 4). After testing the primary stability by movement, a wound suture is performed without the use of a drain. Post-operatively, fixation of the knee in the brace is rigid for 2 days, followed by 0–60 degrees for 2 weeks, then 0–90 for 4 weeks. After six weeks, full loading of the knee joint is gradually allowed.

## DISCUSSION

The above methods of defect treatment produce good results in most cases. Finding a suitable method of chondral defect treatment with reliable long-term results is diffi-



**Fig. 3** Pridie technique.



**Fig. 4** Status after MSC carrier implantation.

cult. It is not possible to determine exactly which procedure is better for a particular type of defect, age of the patient, etc. Microfractures of the base of the defect are considered the gold standard in the treatment of chondral defects, although they have their limitations. The ligamentous repair tissue created is less robust and less resistant than the original hyaline type of cartilage (30). The effect of this surgical technique is less, especially in patients over 40 years of age and in those where the defect is larger than 2.5 cm<sup>2</sup>. In the long term, it does not prevent the onset and progression of degenerative changes. The currently available systematic analyses of clinical results indicate an effective

improvement in knee function in the first 2 years after microfracture, after which there is a gradual deterioration (31). To improve the results, the technique of microfracture of the base of the defect with implantation of a carrier that promotes the ingrowth of mesenchymal stem cells and their differentiation into a chondrogenic line has been used, thereby contributing to the formation of new cartilaginous tissue (20, 21). The results of AMIC therapy give better results than microfracture alone in prospective studies (22). The AMIC method is safe, functional and effective for small to moderate (2 × 3 cm) cartilage defects, especially in the knee. Most clinical studies report that cell therapy with autologous chondrocytes gives equal or better results than mosaicplasty (32). Transplantation of cultured autologous chondrocytes (ACIs) is indicated for circumscribed deep chondral and osteochondral defects of the weight-bearing joints in younger patients ideally under 40 years of age within 3 cm<sup>2</sup>. Histological examination results showed the formation of a mixture of fibrous and hyaline cartilage and type II collagen and proteoglycans were demonstrated. The resulting tissue is softer, well integrated with the subchondral bone (33). The disadvantages of ACI remain its economic cost, the two-step surgical procedure and the harvesting of healthy cartilage, which entails pain from the donor tissue harvest site in up to 15% of patients (34). Another problem is the difficulty of in vitro expansion of chondrocytes and the difficulty of culturing with preservation of the quality and quantity of the harvested and subsequently implanted cells. In contrast, the use of cultured mesenchymal stem cells has the advantages of less invasive harvesting under local anaesthesia, one surgical procedure on the affected joint. MSCs also have a higher proliferative capacity than chondrocytes, which does not decrease significantly with patient age. Donor age and sex do not significantly affect the expansion capacity of MSCs. At our department, we perform bone marrow aspirate collection from the iliac bone flap. In their dissertation, the authors (35) perform quantitative and qualitative analysis of bone marrow cells from different sampling sites. The concentration of MNCs (MonoNuclear Cells) was significantly higher in the bone marrow aspirate taken from the hip bone flap. The median number of MNCs obtained from the tibia after sedimentation was  $5.4 \times 10^6$  MNCs/ml, whereas  $20.5 \times 10^6$  MNCs/ml were obtained from the hip bone flap. The measurement showed statistical significance and a greater proportion of MSCs to MNCs originating from the hip flap (5.2%), whereas the proportion was only 1.0% for the knee. Qualitative analysis focusing on immunophenotyping, viability, yielded comparable results for both sampling sites. The 3D Hyalofast carrier used in our study provides support to the implanted stem cells and allows their incorporation into the surrounding tissue and, conversely, cells from the surrounding cartilage and subchondral bone into the implant.

## CONCLUSION

Current surgical methods of treating damaged cartilage have very good results according to studies and our experience. The possibility of introducing new methods in



the form of the application of cultured mesenchymal stem cells represents a significant advance in the field of regenerative medicine.

## REFERENCES

1. Lüllmann-Rauch R. Histologie. Praha: Grada Publishing, 2012; 122–5.
2. Link TM, Stahl R, Woertler K. Cartilageimaging: motivation, techniques, current and future significance. *Eur Radiology*. 2007; 17: 1135–46.
3. Link TM. MR Imaging in Osteoarthritis: Hardware, Coils and Sequences. *Radiol Clin North Am*. 2009; 47: 617–32.
4. Burstein D, Gray M. New MRI techniques for imaging cartilage. *J Bone Joint Surg Am*. 2003; 85: 70–7.
5. Jeffrey DR, Watt I. Imaging hyaline cartilage. *Br J Radiol*. 2003; 73: 777–87.
6. Quaia E, Toffanin R, Guglielmi G, et al. Fast T2 mapping of the patellar articular cartilage with gradient and spin-echo magnetic resonance imaging at 1.5T: validation and initial clinical experience in patients with osteoarthritis. *Skeletal Radiol*. 2008; 37: 511–7.
7. Van Outeren MV, Waarsing JH, Brouwer RW, et al. Is a high tibial osteotomy (HTO) superior to non-surgical treatment in patients with varus malaligned medial knee osteoarthritis (OA)? A propensity matched study using 2 randomized controlled trial (RCT) datasets. *Osteoarthritis Cartilage*. 2017; 25: 1988–93.
8. Kim KI, Seo MC, Song SJ, et al. Change of Chondral Lesions and Predictive Factors After Medial Open-Wedge High Tibial Osteotomy With a Locked Plate System. *Am J Sports Med*. 2017; 45: 1615–21.
9. Johnson LL. Arthroscopic abrasion arthroplasty: historical and pathologic perspective: Present status. *Arthroscopy*. 1986; 2: 54–69.
10. Pridie KW. A Method of Resurfacing Osteoarthritic Knee Joint. *J Bone Jt Surg*. 1959; 41-B: 211–28.
11. Ficat RP, Ficat C, Gedeon P. Spongialisation: Spongialization: a new treatment for diseased patellae. *Clin Orthop Relat Res*. 1979; Oct(144): 74–83.
12. Steadman JR, Rodkey WG, Rodrigo JJ. Microfracture: Surgical Technique and Rehabilitation to Treat Chondral Defects. *Clin Orthop*. 2001; 391: 362–9.
13. Saltzman BM, Leroux T, Cole BJ. Management and Surgical Options for Articular Defects in the Shoulder. *Clin Sports Med*. 2017; 36(3): 549–72.
14. Thomas M, Jordan M, Hamborg-Petersen E. Arthroscopic Treatment of Chondral Lesions of the Ankle Joint. Evidence-Based Therapy. *Der Unfallchirurg*. 2016; 119(2): 100–8.
15. Peterson L, Menche D, Grande D. Chondrocyte Transplantation – an Experimental Model in the Rabbit. *Trans Orthop Res Soc*. 1984; 9: 218.
16. Brittberg M, Lindahl A, Nilsson A, Ohlsson C, Isaksson O, Peterson L. Treatment of Deep Cartilage Defects in the Knee with Autologous Chondrocyte Transplantation. *N Engl J Med*. 1994; 331(14): 889–95.
17. Ehmann YJ, Esser T, Seyam A, et al. Low Postoperative Complication Rate with High Survival Rate and Good Clinical Outcome 9 Years after Autologous Chondrocyte Transplantation of the Knee Joint. *Arch Orthop Trauma Surg*. 2023; 143(5): 2665–74.
18. Hangody L, Ráthonyi GK, Duska Z, et al. Autologous Osteochondral Mosaicplasty. *J Bone Jt Surg*. 2004; 86(Suppl 1): 65–72.
19. Hangody L, Várshelyi G, Hangody LR, et al. Autologous Osteochondral Grafting-Technique and Long-Term Results. *Injury*. 2008; 39(Suppl 1): 32–9.
20. Irion VH, Flanigan DC. New and emerging techniques in cartilage repair: other scaffold-based cartilage treatment options. *Oper Tech Sports Med*. 2013; 21: 125–37.
21. Schüttler KF, Struwer J, Rominger MB, Rexin P, Efe T. Repair of a chondral defect using a cell free scaffold in a young patient – a case report of successful scaffold transformation and colonisation. *BMC Surgery*. 2013; Apr 16(13): 11.
22. Steinwachs MR, Gille J, Volz M, et al. Systematic Review and Meta-Analysis of the Clinical Evidence on the Use of Autologous Matrix-Induced Chondrogenesis in the Knee. *Cartilage*. 2019 Dec; 13(Suppl 1): 42S–56S.
23. Otašević T, Vališ P, Rouchal M, Novák J, Repko M, Šprlákova-Puková A. Two-year Result of Modified AMIC Technique for Treatment of Cartilage Defects of the Knee. *Acta Chir Orthop Traumatol Cech*. 2020; 3: 167–74.
24. Kazuhiro S, Kanno M, Miharada K, et al. Mesenchymal Progenitors Able to Differentiate into Osteogenic, Chondrogenic, and/or Adipogenic Cells in Vitro Are Present in Most Primary Fibroblast-like Cell Populations. *Stem Cells (Dayton, Ohio)*. 2007; 25(7): 1610–17.
25. Fortier LA, Potter HG, Rickey EJ, et al. Concentrated Bone Marrow Aspirate Improves Full-Thickness Cartilage Repair Compared with Microfracture in the Equine Model. *J Bone Joint Surg Am*. 2010; 92(10): 1927–37.
26. Gobbi A, Karnatzikos G, Scotti C, Mahajan V, Mazzucco L, Grigolo B. One-Step Cartilage Repair with Bone Marrow Aspirate Concentrated Cells and Collagen Matrix in Full-Thickness Knee Cartilage Lesions: Results at 2-Year Follow-Up. *Cartilage*. 2011; 2(3): 286–99.
27. Nejadnik H, Hui JH, Choong EPF, Tai BCH, Lee EH. Autologous Bone Marrow-Derived Mesenchymal Stem Cells versus Autologous Chondrocyte Implantation: An Observational Cohort Study. *Am J Sports Med*. 2010; 38(6): 1110–6.
28. Havlas V, Kos P, Jendelová P, Lesný P, Trč T, Syková E. Comparison of Chondrogenic Differentiation of Adipose Tissue-Derived Mesenchymal Stem Cells with Cultured Chondrocytes and Bone Marrow Mesenchymal Stem Cells. *Acta Chir Orthop Traumatol Cech*. 2011; 78(2): 138–44.
29. Beane OLS, Darling EM. Isolation, Characterization, and Differentiation of Stem Cells for Cartilage Regeneration. *Ann Biomed Eng*. 2012; 40(10): 2079–97.
30. Luyten FP, Vanlauwe J. Tissue engineering approaches for osteoarthritis. *Bone*. 2012; 51: 289–96.
31. Mithoefer K, McAdams T, Williams RJ, Kreuz PC, Mandelbaum BR. Clinical Efficacy of the Microfracture Technique for Articular Cartilage Repair in the Knee: An evidence-based systematic analysis. *Am J Sports Med*. 2009; 37: 2053–63.
32. Richter DL, Schenck RC, Wascher DC, Treme G. Knee Articular Cartilage Repair and Restoration Techniques: A Review of the Literature. *Sports Health*. 2016; 8(2): 153–60.
33. Šťastný E, Trč T, Philippou T, Přidal J, Bělík D. Management of damaged articular cartilage and osteoarthritis – surgical treatment. *Internal Med*. 2018; 20(1): 32–7.
34. Matricali G, Dereymaeker G, Frank L. Donor Site Morbidity after Articular Cartilage Repair Procedures: A Review. *Acta Orthop Belg*. 2010 Oct; 76(5): 669–74.
35. Neckář P. Modern therapy of chondral joint defects (Doctoral dissertation). Prague: Charles University, 2023; 57–8.