

# Delayed-Onset Muscle Soreness of the Psoas Major Muscle Following Abdominal Training: Case Report

Laura Gabriela Silva<sup>1</sup>, Victor Sudário Takahashi<sup>2</sup>, José Luiz Masson de Almeida Prado<sup>3</sup>, Henrique Shimidu<sup>4</sup>, Luís Henrique Paiva D'Elia<sup>5</sup>, Márcio Luís Duarte<sup>2,6,\*</sup>

## ABSTRACT

Edema of the psoas major muscle can indicate various pathologies, such as infection, malignancy, and trauma, but it can also result from benign causes like delayed-onset muscle soreness (DOMS). This article presents the case of a 44-year-old female patient who developed DOMS in the psoas major after participating in an intense abdominal workout. The patient reported hip pain that began a day after the workout, which was confirmed by magnetic resonance imaging (MRI) revealing significant edema in the psoas major muscles, particularly on the right side. Conservative treatment with rest and analgesics led to full recovery within two weeks. DOMS, typically associated with eccentric exercises, can be mistaken for more serious conditions, but its recognition is crucial to avoid unnecessary investigations and interventions. This case highlights the importance of clinical history and imaging findings in distinguishing DOMS from other causes of muscle edema, emphasizing the need for accurate diagnosis to ensure appropriate management.

## KEYWORDS

magnetic resonance imaging; psoas muscles; delayed-onset muscle soreness

## AUTHOR AFFILIATIONS

<sup>1</sup> Centro Universitário Atenas, Paracatu-MG, Brazil

<sup>2</sup> Universidade de Ribeirão Preto Campus Guarujá, Guarujá-SP, Brazil

<sup>3</sup> Fleury Medicina e Saúde, São Paulo-SP, Brazil

<sup>4</sup> Hospital Samaritano, São Paulo-SP, Brazil

<sup>5</sup> Live Core Funcional, Santos-SP, Brazil

<sup>6</sup> Diagnósticos da América S.A. – DASA, São Paulo-SP, Brazil

\* Corresponding author: Universidade de Ribeirão Preto Campus Guarujá. Avenida Dom Pedro I, 3300 Guarujá-SP, Brazil. ZIP CODE: 11440-003; e-mail: marcioluisduarte@gmail.com

Received: 13 April 2024

Accepted: 26 August 2024

Published online: 22 October 2024

Acta Medica (Hradec Králové) 2024; 67(2): 69–71

<https://doi.org/10.14712/18059694.2024.23>

© 2024 The Authors. This is an open-access article distributed under the terms of the Creative Commons Attribution License (<http://creativecommons.org/licenses/by/4.0>), which permits unrestricted use, distribution, and reproduction in any medium, provided the original author and source are credited.

## INTRODUCTION

The psoas major is a muscle attached to the T12-L4 vertebral bodies and the L1-L5 transverse processes at its origin. Its primary function is hip flexion, but it also contributes to lateral flexion of the spine (1). Edema of the psoas muscle is a non-specific finding that, while not commonly observed, can indicate a variety of conditions. One of the primary causes of psoitis is infection, which can occur either directly due to pathogens like *Staphylococcus aureus* or other Gram-negative bacteria, often following injections or injuries, especially in immunocompromised patients. Psoitis can also arise secondarily from the spread of infections from other organs, such as kidney abscesses, gastrointestinal inflammatory diseases, osteomyelitis, and other conditions (2). Trauma or injury can also cause isolated swelling or inflammation of the psoas muscles. In elderly individuals, spontaneous tendon tears can occur even without prior injury, leading to high signal intensity in the iliopsoas muscle near the injury site (3).

Edema in the psoas muscle can also result from malignancy, whether from a primary tumor or metastasis. However, one of the rarer causes of such edema is focal myositis, a benign inflammatory condition of unknown origin. Focal myositis can be mistaken for sarcomas, deep vein thrombosis, or infectious processes but is distinguished by its spontaneous improvement and responsiveness to non-steroidal anti-inflammatory drugs (NSAIDs). Although generally benign, focal myositis may recur. Given its generally good prognosis, it is important to differentiate it from infections or thrombosis. Less common causes of psoas muscle edema include paralysis atrophy, rhabdomyolysis, retroperitoneal fibrosis, or the presence of a foreign body (2).

The following is a rare case of psoas major delayed-onset muscle soreness (DOMS) due to bilateral stretching of the psoas muscles in a 44-year-old female patient.

## CASE REPORT

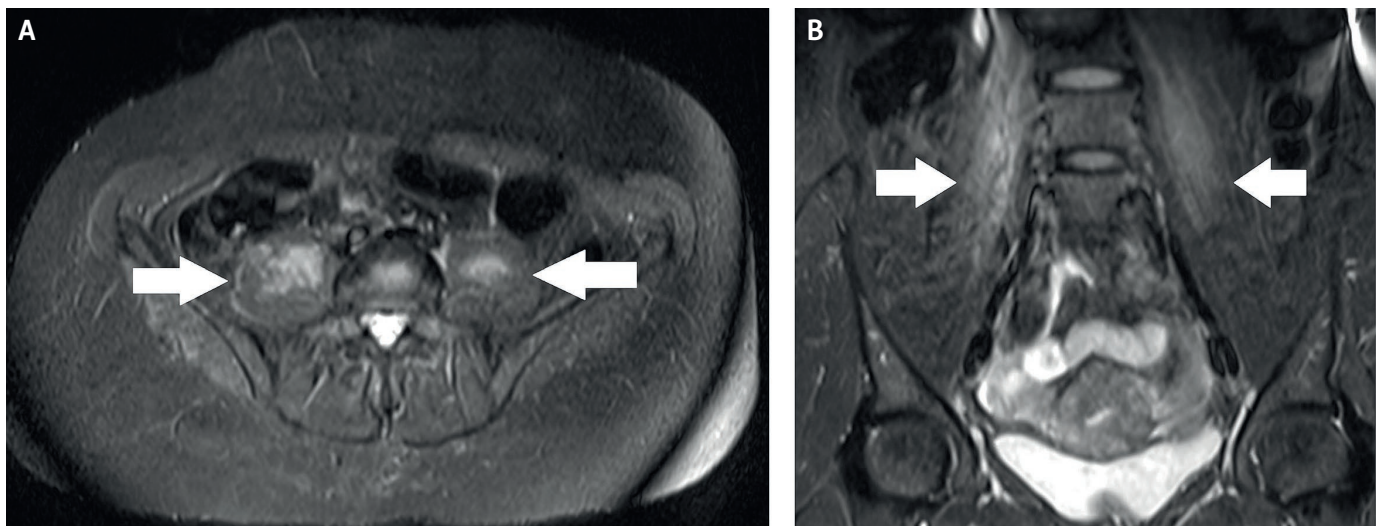
A 44-year-old woman presented with hip pain persisting for two days. She reported that the pain began the day after participating in a 40-minute abdominal workout, which she had also attended two days prior. She denied any history of surgery, trauma, or numbness in her lower limbs. She weighs 70 kg and is 163 cm tall. She has worked as a bridal store manager for 25 years, where she spends all day wearing high heels and frequently climbs up and down stairs. Although she engaged in weight training, she was not accustomed to abdominal training like the ones she had recently attended.

During the physical examination, she exhibited normal mobility in her lower limbs but experienced pain when flexing and rotating her right hip, with preserved strength. Positive findings were noted on iliopsoas, Stinchfield, and Ludloff tests due to pain. The magnetic resonance imaging (MRI) was performed two days after the pain started and revealed significant edema in the psoas major muscle bilaterally, more pronounced on the right side, consistent with DOMS of the psoas major muscles (Figure 1).

The patient rested and received analgesic treatment with dipyrone and physiotherapy, resulting in resolution of pain within two weeks. She subsequently resumed her usual weight training routine.

## DISCUSSION

DOMS is a condition marked by the appearance of muscle pain 1 to 2 days after performing an unfamiliar exercise. It is commonly linked to exercises that involve eccentric (lengthening) muscle contractions, as demonstrated in the report (4). Pain related to DOMS usually peaks between 24 and 72 hours after physical activity and then gradually subsides. This clinical pattern differs from muscle strains, where pain occurs immediately, and this distinction is crucial for accurate diagnosis (5).



**Fig. 1** T2 FAT SAT MRI in axial section (A) and coronal section (B) shows significant edema in the psoas major muscle bilaterally (white arrows), more pronounced on the right side, consistent with delayed-onset muscle soreness of the psoas major muscles.

This condition may involve temporary muscle damage visible at a microscopic level, along with elevated plasma levels of creatine kinase (CK) and, in severe instances, myoglobin in the urine. On a CT scan, a decrease in muscle attenuation and an increase in muscle volume may be observed. Ultrasound imaging can reveal edema as an increase in muscle echogenicity. On MRI, T2-weighted imaging using chemically selective fat suppression and STIR sequences, the affected muscles exhibit high signal intensity, with the amount of muscle edema on MRI correlating with the serum CK level. There is also some correlation between the intensity of pain (experienced during passive muscle extension) and the volume of muscle edema observed on MRI.<sup>(4)</sup> The greater intensity involvement of the right psoas major muscle in the patient reported is related to the process of motor development not trained for ambidexterity for motor coordination, there is, in the process of fatigue (strenuous physical activity), an overload on the dominant side, which in the case of the patient described, who was right-handed, the largest edema visible on MRI was in the right psoas major muscle.

DOMS does not involve any visible fiber disruption or tears. However, in some instances, may cause diffuse edema in the affected muscle belly, which does not show the characteristic “feathery” pattern seen in strains and lacks perifascial fluid<sup>(5)</sup>. If the exercise that caused the soreness targeted a specific set of muscles, the imaging findings will be confined to those areas, as in the case reported in which several types of abdominal exercises overload the psoas major muscles. In contrast, if multiple muscle groups were involved, the pattern may be more widespread<sup>(4)</sup>. Symptoms typically resolve, and muscle function is restored within 10 to 12 days, while abnormal signal intensity on fluid-sensitive MRI images can persist for up to 80 days<sup>(5)</sup>.

Differential diagnosis is complex; pain caused by psoas major DOMS can be mistaken for various other diseases, including other musculoskeletal pathologies or visceral causes such as ureteral stones, salpingitis, hip arthritis, femoral bursitis, colon diverticulitis, and colon cancer<sup>(1)</sup>.

Regarding treatment, the conservative approach is commonly utilized. Non-pharmacological treatments include specific activity modification and physiotherapy. Additionally, NSAIDs are used for pharmacological purposes. Most patients respond well to conservative treatment and achieve full recovery<sup>(6)</sup>.

## CONCLUSION

While edema in the psoas major muscle is commonly associated with various pathological conditions such as infection, malignancy, and trauma, it can also occur due to more benign causes like DOMS. The case presented here highlights the importance of considering DOMS in the differential diagnosis of psoas muscle edema, particularly in individuals who engage in unfamiliar or intense physical activities. The patient’s symptoms and imaging findings were consistent with DOMS, and she responded well to conservative treatment with rest and analgesics, with full recovery within two weeks.

This case underscores the need for clinicians to be aware of the distinct clinical and imaging features of DOMS to avoid unnecessary investigations and interventions. Recognizing the self-limiting nature of DOMS and differentiating it from other more serious conditions can prevent misdiagnosis and ensure appropriate management. Furthermore, this case illustrates the relevance of patient history, particularly recent physical activity, in guiding the diagnostic process, and also the importance of adequate monitoring by professionals during physical activity to guide the practitioner and avoid injuries.

Future studies could explore the mechanisms underlying DOMS in muscles like the psoas major, which are not typically emphasized in the context of this condition and investigate optimal management strategies for patients experiencing significant discomfort.

## REFERENCES

1. Tufo A, Desai GJ, Cox WJ. Psoas syndrome: a frequently missed diagnosis. *J Am Osteopath Assoc.* 2012 Aug; 112(8): 522–8.
2. Voloshin AG, Smirnova NV. Paraspinal and Iliopsoas Edema as a Marker of an Iliofemoral Thrombosis: Case Series Report. *SOJ Ortho Rehab.* 2022; 2(1): 1–4.
3. Rajakulasingam R, Azzopardi C, Dutton P, et al. Spontaneous Isolated Iliopsoas Tendon Tear in Elderly—Case Report and Review of Literature. *Indian J Radiol Imaging.* 2021; 31(3): 719–720.
4. McMahon CJ, Wu JS, Eisenberg RL. Muscle edema. *AJR Am J Roentgenol.* 2010 Apr; 194(4): W284–92.
5. Guermazi A, Roemer FW, Robinson P, Tol JL, Regatte RR, Crema MD. Imaging of Muscle Injuries in Sports Medicine: Sports Imaging Series. *Radiology.* 2017 Mar; 282(3): 646–663. Erratum in: *Radiology.* 2017 Dec; 285(3): 1063.
6. Dydyk AM, Sapra A. Psoas Syndrome. 2023 Jun 21. In: *StatPearls* (Internet). Treasure Island (FL): StatPearls Publishing, 2024.