

# Oral Candidal Infection Misdiagnosed as a Tumour

Wail Abou Assaf<sup>1</sup>, Martin Kapitán<sup>1</sup>, Luboš Tuček<sup>1</sup>, Jan Laco<sup>2</sup>

## ABSTRACT

A case report on a 70-year-old male patient with atypical candidal infection on the palate that was misdiagnosed for a tumour based on clinical examination.

The lesion was an accidental finding when the patient was at a registered dentist for a preventive check-up.

## KEYWORDS

oral candidosis; tumour; immunodeficiency; hematological disorders; acquired coagulopathies

## AUTHOR AFFILIATIONS

<sup>1</sup> Department of Stomatology, University Hospital Hradec Králové, Charles University, Faculty of Medicine in Hradec Králové, Czech Republic

<sup>2</sup> Fingerland Department of Pathology, University Hospital Hradec Králové, Charles University, Faculty of Medicine in Hradec Králové, Czech Republic

\* Corresponding author: Department of Stomatology, University Hospital Hradec Králové, Sokolská 581, Czech Republic, Hradec Králové, 50005, Czech Republic; e-mail: wail.assaf@yahoo.com

Received: 14 May 2023

Accepted: 11 January 2024

Published online: 21 March 2024

Acta Medica (Hradec Králové) 2023; 66(3): 128–131

<https://doi.org/10.14712/18059694.2024.6>

© 2024 The Authors. This is an open-access article distributed under the terms of the Creative Commons Attribution License (<http://creativecommons.org/licenses/by/4.0>), which permits unrestricted use, distribution, and reproduction in any medium, provided the original author and source are credited.

## CASE REPORT

The patient comes on the recommendation of a registered dentist for examination of the oral cavity, specifically palate. Patient is treated for type 2 diabetes mellitus, arterial hypertension, with no known allergies. Also, it is mentioned in his history that he had bypass surgery. His medication includes biguanides, dipeptidyl peptidase 4 (DPP-4) inhibitors, direct factor Xa inhibitors, Angiotensin-converting enzyme inhibitors, beta blocking agents, cardiac glycosides, aldosterone antagonists, HMG-CoA reductase inhibitors, peroral glucocorticosteroid. The patient is a non-smoker.

## RECENT HEALTH CONDITION

The patient was examined at a registered general dentist, where an accidental finding was seen in the palatal area and an examination at Dentistry Department of the University Hospital Hradec Králové was recommended. The patient reports that the medication was changed from Warfarin (Oral anticoagulant) to Xarelto (direct factor Xa inhibitor) 1 month before. He is not aware of any injury in the area of the lesion, the treatment at the registered dentist took place without anaesthesia. Extraoral and intraoral clinical examination showed face without asymmetry, facial skin without pathological findings, regional lymph nodes not palpable, teeth are incomplete as the patient wears partial removable denture for the upper jaw. Furthermore, blue-violet prominence palpably painless present on the hard palate mucosa without epithelial damage (Figure 1a) could be found. More evident part of the lesion is on the left side of the midline of the size 12 × 15 mm (Figure 1a), other mucous membranes are without pathological findings.

## CLINICAL DIAGNOSIS

Traumatic submucosal haemorrhage (due to incorrect brushing technique, suction effect, injury caused by foreign body), capillary haemangioma.

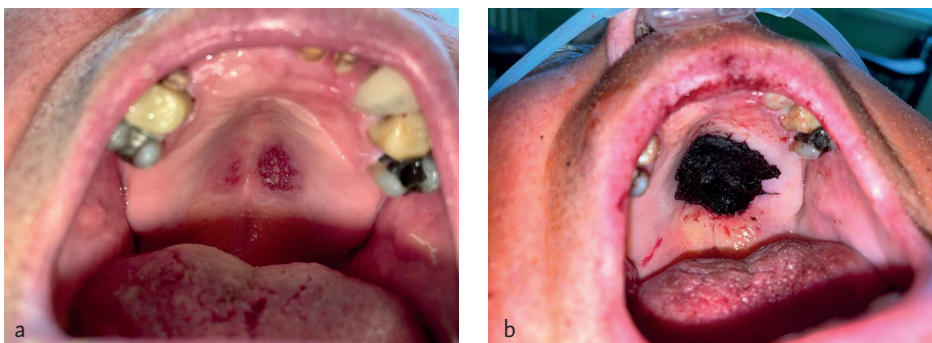
On the first visit at the Dentistry Department of the University Hospital Hradec Králové, it was concluded that it is very likely that the lesion is based on submucosal haemorrhage – very likely that the bleeding is due to medication changes in anticoagulant therapy. As a previous trauma cannot be ruled out, we advised the patient

not to traumatize the mucous membrane of the oral cavity (gentle use of toothbrush for instance), and a follow up in one month. After the month during the follow up, the patient did not experience any difficulties and showed no complaints. The extraoral and intraoral clinical examination showed no changes compared with the previous visit. Clinical diagnosis was changed to possibility of tumor, such as haemangioma on the palate and treatment plan was excisional biopsy under sedation.

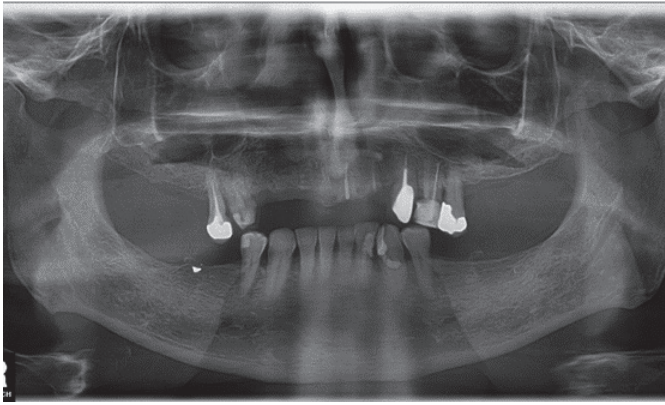
## PROCEDURE

Under analgo-sedation, greater palatine nerve and nasopalatine nerve blocks were done using 4 ml of Supracain 4% (articaine hydrochloride 40 mg and 1 : 200,000 0.005 mg/ml adrenaline – Zentiva, ČR) local anaesthetic was injected, in attempt for anaesthesia and bleeding control. Excisional biopsy was made with the use of scalpel Blade 15, in addition for electrocoagulation device for haemostasis. Specimen excised was of 2 cm × 2 cm including the safe margins of 0.5 cm. The defect on the palate was covered with Surgicel (Oxidised regenerated cellulose, absorbable haemostat – Ethicon New Jersey, USA) stitched to the margins of the palatal mucosa, as shown in (Figures 1a and 1b). The specimen was sent to histopathological examination. The patient came a week later for a check-up and showed no complaints. Histological findings: In the surface squamous epithelium, especially in the superficial parts, there are numerous neutrophilic granulocytes and fungal fibres with the appearance of candida (positive silver staining according to Grocott). Beneath epithelium, there is mixed inflammatory infiltrate with foci of old and recent haemorrhage and scarring. Due to the fragmentation of the material, it is difficult from a microscopic point of view to reliably comment on the completeness of the lesion removal. Dysplastic changes or malignant tumor were not present. Swab for cultivation was made for further treatment at the periodontology and oral diseases department, and as initial treatment Borax glycerine and chlorohexidine mouth washes were prescribed.

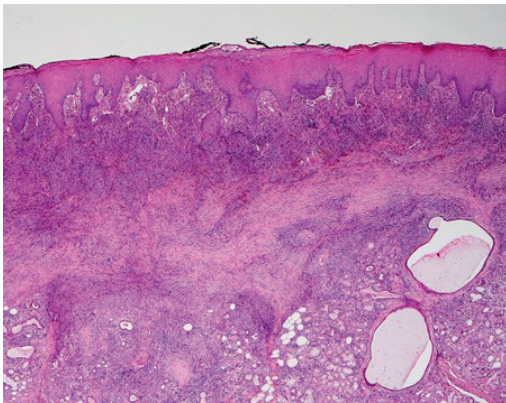
On the third follow up, the patient stated that for 14 days he experienced flu symptoms, (cough, runny nose) – the patient was complaining of fluid coming out of his nose while drinking or rinsing. Based on clinical examination, 2 mucosal defects were present on the hard palate, one was on the left side with exposed necrotic bone. The



**Fig. 1** (a) Picture of the patient's oral cavity, focused on the lesion located on the palate. (b) Picture showing absorbable haemostat (Ethicon, New Jersey, USA) stitched to the margins of the palatal mucosa after the excision of the lesion.



**Fig. 2** OPG: Incomplete dentition, radices 21, 22, teeth 15, 24, 23 endodontically treated in the area of 46 six we can see small radiopaque particle with estimated size  $2 \times 1$  mm – probably part of the amalgam filling, which was not removed during extraction of 46.



**Fig. 3** On the surface of the specimen there is acanthotic squamous epithelium. Beneath epithelium there is mixed inflammatory infiltrate with haemorrhage and scarring extending to the minor salivary gland with dilated ducts (bottom right). (Hematoxylin-eosin, original magnification  $40\times$ )

Note: The black dye on the epithelial surface is the artificially flowing ink used during handling of the specimen to mark the resection margins.

other defect was in the midline of the hard palate, with oronasal fistula that was possible to probe. As a temporary treatment, the defects were etched with 30% hydrogen-peroxide and an operation was planned for closing the oro-nasal communication, otherwise there were no signs of recurrence of the lesion.

## DISCUSSION

Benign red lesions in the oral cavity can be associated with systemic diseases, especially haematological disorders. Megaloblastic anaemia also known as pernicious anaemia is associated with Moeller-Hunter glossitis (Beefy-Red tongue). Morbus Rendu-Osler-Weber also known as telangiectasia hereditaria hemorrhagica, shows multiple telangiectasia and small angiomas in the oral cavity. Acquired coagulopathies also play a role in formation of red lesions, such as patients using oral anticoagulants as small ecchymosis or hematomas can be noticed on different body parts including the oral cavity if a small injury was experienced.

To a more serious extent, malignant lesion can also be included in the differential diagnosis, persisting red lesions in the oral cavity can encompass extra-nodal lymphomas, leukemias (more specifically acute myeloid leukemias), carcinoma in situ in cases of erythroplakia or atypical presentation of squamous cell carcinoma in which complaints such as pain will evoke in progression of the lesion and ulceration.

These lesions often manifest in different shades of redness, which makes their identification crucial in oral examinations. Extra-nodal lymphomas and hematological malignancies can present as a painless palpable mass in the oral cavity, while squamous cell carcinoma, the most common oral cancer can exhibit a reddish non ulcerative appearance unlike the usual.

Red malignant lesions can also be encountered in suppressed immunity, Kaposi's sarcomas caused by Human herpesvirus 8 can be seen in patients with altered immunity, such as HIV positive patients or patients on immunosuppressants medications after organ transplants.

Speaking of immunity, autoimmune diseases such as pemphigoid, pemphigus in addition to linear IgA disease take a spot in the list of red lesions in the oral cavity. Identification of these disorders is essential for therapy planning, ranging for surgical excision and chemotherapies/radiotherapies for malignant lesions to immunosuppressive medications in autoimmune diseases.

Mycotic infection in the oral cavity represents in most cases oral candidosis. The major causes of candidosis are due to *Candida albicans* or non-*albicans* species such as (*C. glabrata*, *C. crusei*, *C. tropicalis* a *C. dubliniensis*). Predisposing factors can be local and systemic. Systemic factors include endocrine and metabolic disorders (eg. diabetes mellitus), haematological disorders -Marrow aplasia, and primary/secondary immunodeficiency. Regarding local factors, bad oral hygiene comes in the first place as plaque accumulation gives a substance for overgrowth. Hyposilia, prosthesis and the use of corticosteroids also play a role, too. Candidal infections, especially chronic erythematous form that is associated with complete or partial prosthesis are treated with anti-mycotics and good oral hygiene. Anti-mycotics involve several groups {Imidazole, Triazoles, Polyens, Allylamines}. Some of these medications should be avoided in the case the patient is on certain drugs as there can be drug-interactions.

Drugs such as Ketoconazole-from the Imidazole group and Itraconazole-from the Triazol group, can interact with medications such as steroids, CyA, carbamazepine, digoxin and oral anticoagulant (Warfarin).

In addition to that these drugs should not be given with medication that affect the stomach acidity, such as parasympatholytic and H2 blockers as it leads to poor absorption of the anti-mycotic in the absence of adequate acidity.

Oral candidoses that are associated with red lesions can be acute erythematous candidosis, were the patient complains of tactile tenderness and pain on palpation of the affected area. Usually, this type of candidal infections is seen in patients with good health but in their history, they have been treated with broad spectrum antibiotics causing the bacterial flora to decrease allowing the flourishing of fungal organisms.

The other type is chronic erythematous, also known as atrophic prosthetic candidosis, with chief complaints of burning sensation and pain. The lesion is present at the site of prosthesis (eg. Complete denture). These common symptoms were not present.

### PATIENTS CONSENT

The consent to publish this information was obtained from study participant. We confirm that written proof of consent to publish study participants are available when requested and at any time.

### FUNDING

Supported by project BBMRI-CZ LM2018125.

### REFERENCES

1. Slezák R, Dřízhal I. Atlas chorob ústní sliznice. Praha: Quintessenz, 2004.
2. Bergmeier LA. Oral Mucosa in Health and Disease. A Concise Handbook. Cham, Switzerland: Springer International Publishing, 2018.
3. McNamara KK, Kalmar JR. Erythematous and Vascular Oral Mucosal Lesions: A Clinicopathologic Review of Red Entities. *Head Neck Pathol* 2019; 13(1): 4–15.
4. Fowell C, Vereá Linares C, Jones R, Nishikawa H, Monaghan A. Venous malformations of the head and neck: current concepts in management. *Br J Oral Maxillofac Surg* 2017; 55(1): 3–9.
5. Greenberg MS. Clinical and histologic changes of the oral mucosa in pernicious anemia. *Oral Surg Oral Med Oral Pathol* 1981; 52(1): 38–42.
6. Singh A, Verma R, Murari A, Agrawal A. Oral candidiasis: An overview. *J Oral Maxillofac Pathol* 2014; 18(Suppl 1): S81–S85.
7. Niwa T, Imagawa Y, Yamazaki H. Drug interactions between nine antifungal agents and drugs metabolized by human cytochromes P450. *Curr Drug Metab* 2014; 15(7): 651–79.