

# A Giant Scrotal Neurofibroma in a Child Masquerading as Filariasis: Uncommon Presentation of a Common Disease

Anurag Singh<sup>1</sup>, Gyanendra Singh<sup>2</sup>, Anuragani Verma<sup>3</sup>,  
Yogendra Narayan Verma<sup>4</sup>

<sup>1</sup> Department of Pathology, King George Medical University, Lucknow, India;

<sup>2</sup> Department of Pathology, All India Institute of Medical Sciences Rajkot, Gujarat, India;

<sup>3</sup> Department of Microbiology, King George Medical University, Lucknow, India;

<sup>4</sup> Department of Pathology, Ganesh Shankar Vidyarthi, Medical College, Kanpur, India

Received July 11, 2023; Accepted January 30, 2024.

**Key words:** Neurofibroma – Neurofibromatosis type I – Scrotum – Scrotal mass

**Abstract:** Neurofibroma of the scrotum is a very uncommon benign neoplasm, specifically when it affects teenagers and is not associated with neurofibromatosis type I. To the best of our knowledge, only a couple of cases of neurofibroma in children have been documented. Here, we report a case study of a 17-year-old boy who had a giant scrotal lump for ten years masquerading clinically as filariasis. A provisional diagnosis of benign nerve sheath neoplasm was made based on cytology findings. The lump was surgically removed from the patient, and a histopathological and immunohistochemistry examination established the diagnosis of neurofibroma. The combined clinical, preoperative cytological, histological, and immunohistochemistry findings were not presented in the literature in any of the formerly documented cases of scrotal neurofibroma. The current case expands the spectrum of differential diagnoses for scrotal tumours that clinicians have previously observed.

**Mailing Address:** Gyanendra Singh, MD., Department of Pathology, AIIMS Rajkot, village Khanderi, Parapipaliya, 360001, Gujarat, India; e-mail: gyanendra002@gmail.com

<https://doi.org/10.14712/23362936.2024.5>

© 2024 The Authors. This is an open-access article distributed under the terms of the Creative Commons Attribution License (<http://creativecommons.org/licenses/by/4.0>).

## Introduction

The spermatic cord and epididymis are the major sites of extra-testicular scrotal tumours. Leiomyoma, fibroma, lipoma, and haemangioma are the most frequent benign mesenchymal scrotal tumours (Gupta et al., 2011). Neurofibroma must be considered in the differential diagnosis of scrotal tumours despite its exceptional rarity. To the best of our knowledge, only a few cases of solitary scrotal neurofibroma in children without a relationship with neurofibromatosis type 1 (NF1) have been reported in the English literature (Türkyılmaz et al., 2004; Jaber et al., 2020). Here, we report an extremely uncommon case of a giant scrotal mass in a child that was clinically masquerading as scrotal filariasis with the demonstration of clinical, cytological, histomorphology, and immunohistochemical findings.

## Case report

A 17-year-old boy was evaluated for an isolated, painless, progressively increasing hanging giant scrotal mass that had been present for ten years. The results of a physical examination revealed a massive lump that appeared to originate from the left scrotum and extend up to the left knee, measuring 32.5×8.5 cm (Figure 1A). On palpation, it was difficult to precisely localise its relationship to the spermatic cord and the epididymis. The lump was non-transilluminating, and no hernia was found. An enlarged left inguinal lymph node was also noted, which was firm, mobile, and non-tender on examination. The overlying skin over the lymph node was unremarkable. No abnormality was detected on systemic examination. Ultrasonography revealed a giant hetero-echoic extratesticular mass lesion arising from the left scrotum. Both testes were seen separately from the mass without a hydrocele. Laboratory parameters, including the complete blood count, renal function test, liver function test, and serological examination, were within normal limits. A provisional diagnosis of scrotal filariasis was made based on clinical and radiological evaluation, and the patient was scheduled for fine needle aspiration cytology from the left scrotal mass and inguinal lymph node. The cytology smears from the scrotal mass revealed cellular smears, displaying bland monomorphic spindle-shaped cells with wavy nuclei on a background with few red blood cells. There was no evidence of necrosis or mitotic activity (Figure 1B). The cytology of the scrotal mass was suggestive of benign spindle cell neoplasm, and the possibility of benign nerve sheath neoplasm was considered. The aspiration smears from the lymph node were cellular and showed a reactive population of lymphoid cells on a hemorrhagic background, which was reported as reactive lymphoid hyperplasia (Figure 1C).

The complete excision of the left scrotal mass lesion was performed under general anaesthesia. The mass was completely dissected from the surrounding tissue. The testes and epididymis were not involved. The scrotal mass has firmly adhered to

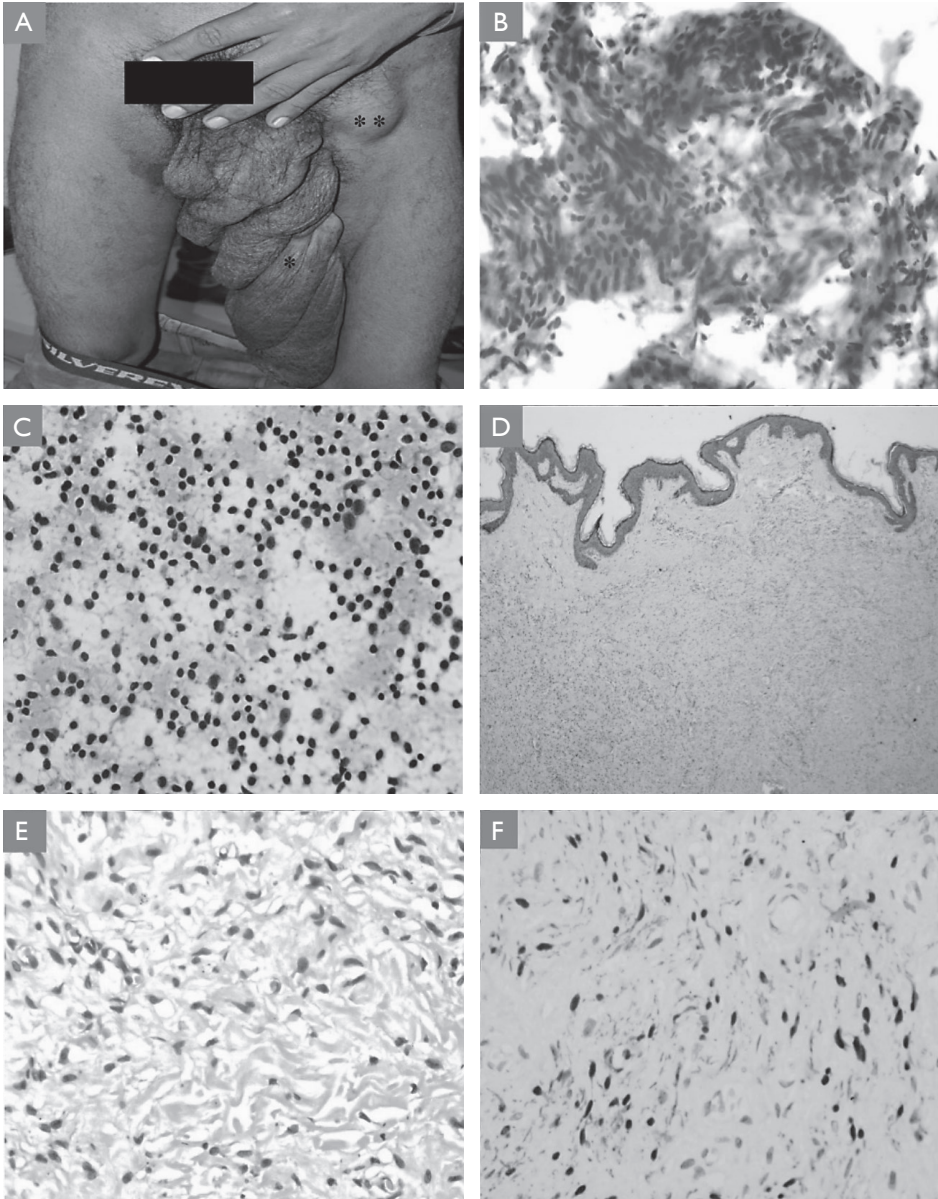


Figure 1 – A) Clinical image of the left scrotal mass\* and enlarged left inguinal lymph node\*\*; B) cytology smear from left scrotal mass displaying bland monomorphic spindle-shaped cells having wavy nuclei and ill-defined cytoplasm (hematoxylin and eosin [H and E] stain, 400×); C) cytology smears from inguinal lymph node displaying reactive population of lymphoid cells (H and E stain, 400×); D) section showing tumour composed of evenly distributed spindle-shaped cells covered by stratified squamous epithelium (H and E stain, 40×); E) section displaying proliferating spindle-shaped cells with wavy nuclei lying in connective tissue stroma composed of delicate collagen bundles (H and E stain, 400×); F) immunohistochemistry displaying positive expression for S-100 protein in tumour cells.

the scrotal wall, which signifies that it most likely originated from subcutaneous connective tissue. The external spermatic fascia, ilioinguinal, and genitofemoral nerves were not related to the tumour. The excised mass measured 33×10×6 cm and was covered by skin; the cut surface was gelatinous grey-white with focal areas of haemorrhage. There was no gross necrosis.

Histopathological examination of the resected mass showed a non-capsulated tumour covered by unremarkable stratified squamous epithelium. The tumour was comprised of uniformly dispersed monomorphic spindle-shaped cells with wavy nuclei, bland chromatin, and poorly defined cytoplasm that were embedded in a stroma that showed sclerosis at places. No mitotic figures or necrosis were discernible (Figure 1D and E). Immunohistochemical examination of the tumour showed positive expression of S100 and vimentin (Figure 1F). Smooth muscle actin, cytokeratin, and desmin were negative in tumour cells. The Ki-67 proliferation index was 1%. A definitive diagnosis of neurofibroma was established on the basis of cytology, histomorphology, and immunophenotypic findings. Retrospectively, the patient has been investigated for a possible link with NF-1, but the radiological and genetic study results were negative. During a six-month follow-up, there was no tumour recurrence.

## Discussion

Neurofibroma is a benign tumour of the nerve sheath that arises from Schwann cells. They can occur in any part of the central or peripheral nervous system, including the neck, thorax, skull, retroperitoneum, and flexure regions of the extremities (Milathianakis et al., 2004). In children, only a couple of scrotal neurofibroma cases without the association of NF1 have been recorded in the literature (Türkyilmaz et al., 2004; Jaber et al., 2020). The scrotal neurofibroma presents as a painful or painless mass and is reported in patients of all ages (Yoshimura et al., 1990; Issa et al., 1993; Gupta et al., 2011; Jaber et al., 2020). In the present case, a 17-year-old boy presented with a painless giant mass of the scrotum. Although the precise origin of the tumour is frequently unknown in cases of scrotal neurofibroma, the majority of these tumours are extra-testicular. The genitofemoral nerve, epididymis, subcutaneous neural tissue, spermatic cords, and tunics have been the origins of scrotal neurofibroma (Yamamoto et al., 1982; Deliveliotis et al., 2002; Singal et al., 2012). The tumour in the present case has been connected to the subepithelial zone of the scrotal wall, suggesting that the subcutaneous neural tissue was the most likely place of origin. Investigations should focus on the clinical and radiological signs of this disease association with NF1, such as café-au-lait macules, long bone cortical thinning, Lisch iris nodules, optic glioma, and a family history of the disease (Mishra et al., 2002; Hosseini et al., 2012). NF1 was not found in the genetic study, and the present case also had no disease-related clinical, radiological, or family history.

In order to provide a provisional diagnosis for superficial masses, aspiration cytology is the preferred, less intrusive diagnostic technique. However, for definitive diagnosis, histology along with the assimilation of immunocytochemistry, is the recommended method that can provide a conclusive diagnosis. On aspiration smears, it is typically impossible to distinguish between neurofibroma and schwannoma, with the exception of cases where schwannoma exhibits Verocay's bodies on cytology (Gupta et al., 2011). Increased cellularity, numerous mitoses, and the presence of necrosis favour the diagnosis of a malignant peripheral nerve sheath tumour (Pekmezci et al., 2015; Verma et al., 2020; Sharma et al., 2021). In the present case, there was no necrosis or mitosis, and the Ki-67 proliferation index was 1%, supporting the diagnosis of neurofibroma.

The preferred course of treatment for these tumours is complete excision, avoiding orchidectomy. An orchidectomy has been done if the tumour has an intratesticular location or if the testicles and the tumour share a common blood supply. In order to rule out malignancy and avoid orchidectomy, the fine needle aspiration cytology or frozen section is also very beneficial (Gupta et al., 2011; Hosseini et al., 2012). The tumour in the current case was extratesticular and provisionally diagnosed as a benign nerve sheath neoplasm by aspiration cytology; hence, both gonads were left intact. Complete excision of the mass has produced positive outcomes in all previously reported cases, with no residual disease or recurrences.

## Conclusion

In the differential diagnosis of scrotal tumours in children, scrotal neurofibroma, a rare benign tumour, should be taken into account. A preoperative diagnosis can be made using radiology and fine-needle aspiration cytology, allowing the right surgical strategy to be established. Excellent outcomes were obtained, with no recurrences following the complete removal of the tumour.

## References

- Deliveliotis, C., Albanis, S., Skolarikos, A., Varkarakis, J., Protogerou, V., Tamvakis, N., Alargof, E. (2002) Solitary neurofibroma of the spermatic cord. *Int. Urol. Nephrol.* **34**, 373–375.
- Gupta, S., Gupta, R., Singh, S., Pant, L. (2011) Solitary intrascrotal neurofibroma: A case diagnosed on aspiration cytology. *Diagn. Cytopathol.* **39**, 843–846.
- Hosseini, M. M., Geramizadeh, B., Shakeri, S., Karimi, M. H. (2012) Intrascrotal solitary neurofibroma: A case report and review of the literature. *Urol. Ann.* **4**, 119.
- Issa, M. M., Yagol, R., Tsang, D. (1993) Intrascrotal neurofibromas. *Urology* **41**, 350–352.
- Jaber, G., Gupta, V., Javaid, U., Mohd, D., Rafae, M. (2020) Solitary intrascrotal neurofibroma in a child: A case report. *J. Pediatr. Adolesc. Surg.* **1**, 101–103.

- Milathianakis, K. N., Karamanolakis, D. K., Mpogdanos, I. M., Trihia-Spyrou, E. I. (2004) Solitary neurofibroma of the spermatic cord. *Urol. Int.* **72**, 271–274.
- Mishra, V. C., Kumar, R., Cooksey, G. (2002) Intrascrotal neurofibroma. *Scand. J. Urol. Nephrol.* **36**, 385–386.
- Pekmezci, M., Reuss, D. E., Hirbe, A. C., Dahiya, S., Gutmann, D. H., Von Deimling, A., Horvai, A. E., Perry, A. (2015) Morphologic and immunohistochemical features of malignant peripheral nerve sheath tumors and cellular schwannomas. *Mod. Pathol.* **28**, 187–200.
- Sharma, M. R., Puj, K. S., Salunke, A. A., Pandya, S. J., Gandhi, J. S., Parikh, A. R. (2021) Malignant peripheral nerve sheath tumor with analysis of various prognostic factors: A single institutional experience. *J. Cancer Res. Ther.* **17**, 106–113.
- Singal, R., Pal Singal, R., Singal, S., Sekhon, A. (2012) Neurofibroma of the scrotum: An unbelievable experience. *Ann. Trop. Med. Public Health* **5**, 370–372.
- Türkyılmaz, Z., Sönmez, K., Karabulut, R., Dursun, A., Işık, I., Başaklar, C., Kale, N. (2004) A childhood case of intrascrotal neurofibroma with a brief review of the literature. *J. Pediatr. Surg.* **39**, 1261–1263.
- Verma, R. K., Gautam, V., Bahl, A., Bal, A. (2020) Malignant peripheral nerve sheath tumor of the parapharyngeal space arising from cervical sympathetic chain: A rare entity. *J. Cancer Res. Ther.* **16**, 630–633.
- Yamamoto, M., Miyake, K., Mitsuya, H. (1982) Intrascrotal extratesticular neurofibroma. *Urology* **20**, 200–201.
- Yoshimura, K., Maeda, O., Saiki, S., Kuroda, M., Miki, T., Usami, M., Kotake, T. (1990) Solitary neurofibroma of scrotum. *J. Urol.* **143**, 823.