

Gallstone Ileus in Octogenarians: Is Cholecystectomy Really Needed?

Nikolaos Koliakos¹, Dimitrios Papaconstantinou¹, Andrianos Serafeim Tzortzis^{2,*}, Efstratios Kofopoulos-Lymeris¹, Anargyros Bakopoulos¹, Konstantinos Nastos¹, Evangelos P. Misiakos¹, Emmanouil Pikoulis¹

ABSTRACT

Gallstone ileus is an uncommon complication of cholelithiasis and occurs when a gallstone migrates through a cholecystoenteric fistula and impacts within the gastrointestinal tract. Surgical intervention remains the treatment of choice, which consists of a full-thickness incision of the visceral wall and removal of the impacted gallstone. In this paper we present the treatment approach of 6 cases of gallstone ileus in octogenarians. In our cohort, intestinal obstruction was resolved through an enterotomy or gastrotomy and lithotomy/stone extraction in every patient. No cholecystectomies were undertaken. Despite the fact that gallstone ileus is diagnosed in small percent of patients suffering from gallstone disease, it accounts for a large proportion of intestine obstruction in patients older than 65 years old. Since accurate diagnosis and timely intervention are vital, providers should be familiar with the diagnostic approach and the treatment of this clinical entity.

KEYWORDS

gallstone ileus; bowel obstruction; intestinal obstruction; treatment

AUTHOR AFFILIATIONS

¹ 3rd Department of Surgery, Medical School, Attikon University Hospital, National and Kapodistrian University of Athens, Athens, Greece

² Medical School, National and Kapodistrian University of Athens, Athens, Greece

* Corresponding author: Medical School, National and Kapodistrian University of Athens, Mikras Asias 75, Athens, Greece
e-mail: andtzortzis@gmail.com

Received: 24 November 2021

Accepted: 8 December 2022

Published online: 16 March 2023

Acta Medica (Hradec Králové) 2022; 65(4): 153–157

<https://doi.org/10.14712/18059694.2023.7>

© 2022 The Authors. This is an open-access article distributed under the terms of the Creative Commons Attribution License (<http://creativecommons.org/licenses/by/4.0>), which permits unrestricted use, distribution, and reproduction in any medium, provided the original author and source are credited.

INTRODUCTION

Gallstone ileus is a rare complication of cholelithiasis that occurs when a gallstone migrates from the gallbladder through a cholecystoenteric fistula, subsequently becoming impacted within the gastrointestinal tract. It is characterized by mechanical obstruction of the bowel and often presents with abdominal distention, vomiting and fever. In the elderly, dehydration, shock, or peritonitis may complicate the clinical presentation (1). Although endoscopic management has been successful in up to 30% of reported cases (2), surgical treatment is warranted in the majority cases (1). Surgical management consists of two components: resolution of acute small bowel obstruction with removal of the impacted gallstone, followed by elective evaluation of the gallstone disease and inflammatory fistulisation (1, 2).

Since Courvoisier published the first series of 131 cases, reporting a mortality rate of 44% in 1890, gallstone ileus remains a rare morbid complication of gallbladder inflammation (3), with the issue of optimal surgical approach and timing of the procedure being still debated. The rarity of the disease, compounded by the scarcity of patient-level data represent a challenge in devising accurate evidence-based management protocols, especially regarding the biliary disease component. Herein, we present the diagnostic and treatment modalities of 6 cases of octogenarian patients suffering from bowel obstruction caused by impacted gallstones.

CASE SERIES

CASE 1

An 83-year-old female patient presented to the emergency department due to complaints of vomiting and abdominal pain which began three days before her admission to our hospital. Physical examination revealed epigastric tenderness. Her past medical history included diabetes, abdominal aortic aneurysm, and atrial fibrillation. One month before presentation, she complained about an atypical right upper quadrant pain and low-grade fever. Computed-tomography (CT) scan with intravenous and oral contrast of the abdomen demonstrated marked gastric dilation and a solid mass of approximately 3.5 cm in size, embedded in the third part of the duodenum (Figure 1a). Exploratory laparotomy via a supraumbilical midline incision was decided upon, whereby duodenotomy, lithotomy and gallstone extraction followed by defect closure were performed. A low-output fistula occurred during the postoperative period, which was managed conservatively, with the patient being discharged in good clinical condition after removal of the drain on postoperative day 25. The patient died of congestive heart failure 18 months after surgery.

CASE 2

An 81-year-old male patient, with a personal history of diabetes mellitus, atrial fibrillation and chronic obstructive lung disease presented to the emergency department

because of dyspnea, abdominal pain and vomiting starting two days ago. Physical examinations revealed right upper quadrant tenderness and crackles on the right lower lung fields. Four months prior to this episode he had experienced pain in the right upper quadrant of his abdomen. CT scan with IV and oral contrast demonstrated distention of stomach and jejunum due to obstruction from an impacted gallstone with air bubbles present within the gallbladder (Figure 1b). The patient underwent laparotomy, with the stone was removed through a 3-cm enterotomy. The length of postoperative stay was prolonged due to aspiration pneumonia; however, the patient was discharged on postoperative day 10 with his thereafter course being uneventful. Two years after the procedure, the patient is alive but reports frequent hospitalization due to exacerbation of chronic obstructive pulmonary disease.

CASE 3

An 85-year-old woman, with a history of hypertension, came to the emergency department due to vomiting and abdominal pain. The patient reported a similar episode of severe back pain relieved by rest and analgesics a few months prior to presentation. Contrast-enhanced CT scan revealed stomach dilation and a solid mass impacted in the first part of the duodenum, as well as air into the gallbladder and the biliary tree (Figure 1c). Via midline laparotomy, the gallstone was palpated and was maneuvered into the stomach where it was retrieved via gastrotomy. The patient had an uneventful postoperative course and was discharged on postoperative day 10. The patient remains in good health two years postoperatively.

CASE 4

An 80-year-old male patient visited the emergency department because of vomiting and abdominal pain. Physical examination revealed abdominal distention and tenderness. His medical history included chronic obstructive pulmonary disease and aortic valve replacement. Approximately sixty days prior to his admission he had experienced an atypical epigastric pain. CT scan with IV contrast showed a mass causing ileal obstruction with air present within the gallbladder (Figure 1d). Eventually, the patient was taken to the operating theatre and underwent an exploratory laparotomy. The site of obstruction was identified by palpation and the gallstone was retrieved after an enterotomy which was subsequently closed. The patient recovered uneventfully and was discharged on postoperative day 10. Four years after the operation the patient is still alive without presenting any symptoms associated with residual gallstone disease.

CASE 5

An 88-year-old female patient with a history of hypertension and dementia presented to the emergency department with fever, abdominal pain, and vomiting. Due to an episode of cholangitis 3 months ago, she underwent endoscopic retrograde cholangiopancreatography. Impacted gallstones into the common bile duct (CBD) that were

removed and CBD double-stenting after a sphincterotomy were performed. Abdominal distention, tenderness and jaundice (bilirubin 4 mg/dl) with increased number of inflammatory markers (WBC 16700/mm³ and CRP 150 mg/dl) needed emergency management. Computer tomography showed ileal obstruction caused by a solid mass plus air in the gallbladder and the biliary tree (Figure 1e). She underwent open surgery, and the stone was located and removed. The patient's post-operative period was complicated by surgical site infection (SSI) however, the patient was discharged on postoperative day 6. Twelve months after the operation she remains in good condition without any biliary-associated complaints.

CASE 6

This is a case of an 82-year-old female patient who presented to the emergency department with complaints of vomiting and abdominal pain. Abdominal examination revealed tenderness, but no distention. Her past medical history included atrial fibrillation, a transient ischemic attack and dementia. A CT scan with IV and oral contrast was performed, that showed jejunal obstruction (Figure 1f) and air in the gallbladder. The abdomen was explored through a midline incision. After the obstruction was identified an enterotomy, lithotomy and defect closure were performed. The patient was uneventfully discharged on postoperative day 8, however he died 6 months later due to an ischemic stroke.

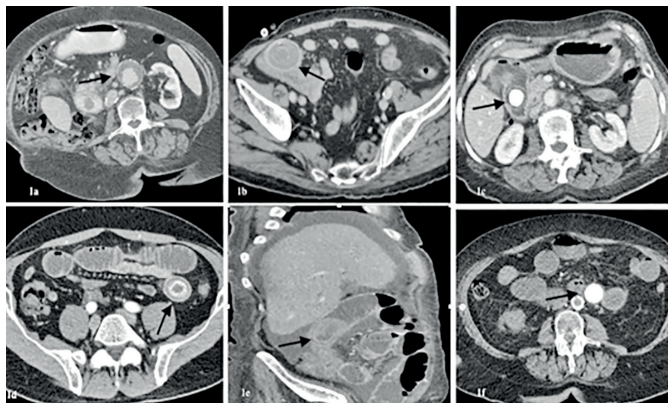


Fig. 1 CT scan with IV and oral contrast showing (a) a solid mass in size of 3.5 cm embedded in the 3rd part of the duodenum (white arrow) in case 1, (b) a gallstone impacted in the jejunum in case 2, (c) a solid mass impacted in the first part of the duodenum, as well as air into the gallbladder and the biliary tree in case 3, (d) a solid mass obstructing the ileum in case 4, (e) ileal obstruction caused by a solid mass in case 5, (f) jejunal obstruction in case 6.

DISCUSSION

Gallstone ileus is diagnosed in 0.3–0.5% of patients suffering from gallstone disease (4). Accounting for almost one fourth of intestine obstructions in patients older than 65 years old, accurate diagnosis and timely intervention are warranted (5). Two possible pathogenetic pathways of a cholecystoenteric fistula have been previously described. The first entails the formation of a fistula between

gallbladder wall and an adjacent hollow viscera, while the second involves migration of gallstones through the common bile duct and the ampulla of Vater after endoscopic sphincterotomy (3).

The possible sites of obstruction include the ileum (60%), the jejunum (15%), the stomach (15%), and the colon (5%) (6). Plain abdominal x-ray and abdominal computed tomography (CT) with intravenous and oral contrast are the diagnostic modalities best used in acute setting (5). The classic radiological findings, called Rigler's triad consisting of pneumobilia or contrast medium within the biliary tract, small bowel obstruction and an ectopic gallstone in the bowel are present in one-third of patients (2, 7).

Surgical management consists of a full-thickness incision of the visceral wall and removal of the impacted gallstone. In cases of duodenal impaction, gently pushing the gallstone to the stomach allows for an easier and safer retrieval. Synchronous impacted gallstone removal, cholecystectomy and fistulectomy can be urgently performed during a single operation (3). Although a planned cholecystectomy following the resolution of acute small bowel obstruction is a feasible option, this is not recommended in older fragile patients (3, 4). It is well worth noting that spontaneous closure of inflammatory cholecystoenteric fistulas in asymptomatic patients has been recorded (8). Synchronous gallbladder carcinoma as an incidental finding is another possibility that should be taken into consideration (9, 10).

Laparoscopic resolution of gallstone ileus is feasible, albeit with a high risk of conversion due to exacerbated small bowel distention and risk of bowel content spillage in the abdominal cavity following enterotomy for stone extraction (11). Other minimal invasive methods such as endoscopic lithotomy, lithotripsy or extraction have been previously described as alternatives to cholecystectomy in fragile patients, however, data on the efficacy of such approaches remain, as yet, limited (3).

Intestinal obstruction was resolved through an enterotomy or gastrotomy and lithotomy/stone extraction in every patient in our cohort. Postoperative mortality is considerable when synchronous cholecystectomy is undertaken and should be factored in when contemplating the optimal surgical approach in elder patients (3). In the present case series follow-up symptoms of cholecystitis, cholangitis and recurrent ileus did not recur, with two registered mortalities being attributable to non-biliary causes (Table 1).

Although omitting cholecystectomy appears to be safe in frail patients, this observation cannot be generalized due to the small number and the narrow demographic range of included cases. Nevertheless, long-term postoperative outcomes regarding biliary-associated complications appear to be low, thus justifying a more conservative approach with regard to the biliary disease component.

CONCLUSION

Gallstone ileus is a rather rare complication of cholecystitis. Surgical treatment of gallstone ileus consists of removal of the impacted gallstone to resolve bowel obstruction in

Tab. 1 Characteristics of patients with gallstone ileus in our series.

Patient	Gender	Age	Comorbidities	CCI	Symptoms of RUQ inflammation preoperatively	Biliary interventions preoperatively	CT findings	Operation	Morbidity	Length of post-operative stay	Postoperative mortality	Mortality
1	F	83	Diabetes, atrial fibrillation	7	RUQP, fever	None	Bouveret's syndrome, air into the gallbladder, gastrographin into the gallbladder	Duodenotomy and lithotomy	Leakage	25	No	18 months
2	M	81	Diabetes, atrial fibrillation, chronic obstructive pulmonary disease	8	RUQP	None	Jejunal obstruction, air into the gallbladder	Enterotomy and lithotomy	Pneumonia	10	No	No
3	F	85	Hypertension	5	Back pain	None	Bouveret's syndrome, air into the gallbladder, pneumobilia	Gastrotomy and lithotomy	No	10	No	No
4	M	80	Chronic obstructive pulmonary disease, metallic aortic valve	6	Epigastric pain	None	Ileum obstruction, air into the gallbladder	Enterotomy and lithotomy	No	10	No	No
5	F	88	Hypertension, dementia	7	RUQP, fever, jaundice	ERCP	Ileum obstruction, air into the gallbladder, pneumobilia	Enterotomy and lithotomy	SSI	6	No	No
6	F	82	Atrial fibrillation, transient ischemic attack, dementia	7	None	None	Jejunal obstruction, air into the gallbladder	Enterotomy and lithotomy	No	8	No	6 months

the acute setting. While cholecystectomy may be contemplated, it is not recommended in older, frail patients. In our case series, intestinal obstruction was resolved through an enterotomy or gastrotomy and lithotomy/stone extraction in every patient with no patient subsequently developing biliary-related adverse events, despite the omission of cholecystectomy. Nevertheless, larger patient series are still necessary to corroborate the safety of leaving the gallbladder in situ, following an episode of gallstone ileus.

REFERENCES

1. Inukai K. Gallstone ileus: a review. *BMJ Open Gastroenterol* 2019; 24: e000344.
2. Al-Habbal Y, Ng M, Bird D, et al. Uncommon presentation of a common disease - Bouveret's syndrome: A case report and systematic literature review. *World J Gastrointest Surg* 2017; 9: 25-36.
3. Nuño-Guzmán CM. Gallstone ileus, clinical presentation, diagnostic and treatment approach. *World J Gastrointest Surg* 2016; 8: 65.
4. Caldwell KM, Lee SJ, Leggett PL, et al. Bouveret syndrome: current management strategies. *Clin Exp Gastroenterol* 2018; 11: 69-75.
5. Chang L, Chang M, Chang HM, et al. Clinical and radiological diagnosis of gallstone ileus: a mini review. *Emerg Radiol* 2018; 25: 189-96.
6. Gurvits GE, Lan G. Enterolithiasis. *World J Gastroenterol* 2014; 20: 17819-29.
7. Chuah PS, Curtis J, Misra N, et al. Pictorial review: the pearls and pitfalls of the radiological manifestations of gallstone ileus. *Abdom Radiol* 2017; 42: 1169-75.
8. Ravikumar R, Williams JG. The operative management of gallstone ileus. *Ann R Coll Surg Engl* 2010; 92: 279-81.
9. Shinoda M, Aiura K, Yamagishi Y, et al. Bouveret's syndrome with a concomitant incidental T1 gallbladder cancer. *Clin J Gastroenterol* 2010; 3: 248-53.
10. Sharma D, Jakheta A, Agarwal L, et al. Carcinoma Gall Bladder with Bouveret's Syndrome: A Rare Cause of Gastric Outlet Obstruction. *Indian J Surg* 2010; 72: 350-1.
11. Halabi WJ, Kang CY, Ketana N, et al. Surgery for gallstone ileus: a nationwide comparison of trends and outcomes. *Ann Surg* 2014; 259: 329-35.